



Deposited via The University of Leeds.

White Rose Research Online URL for this paper:

<https://eprints.whiterose.ac.uk/id/eprint/113571/>

Version: Accepted Version

Article:

Khan, KN, Lord, EC, Arno, G et al. (2018) Detailed Retinal Imaging In Carriers Of Ocular Albinism. *Retina*, 38 (3). pp. 620-628. ISSN: 1539-2864

<https://doi.org/10.1097/IAE.0000000000001570>

(c) 2017 by Ophthalmic Communications Society, Inc. This is an author produced accepted manuscript version of "Khan, KN, Lord, EC, Arno, G et al. (2017) DETAILED RETINAL IMAGING IN CARRIERS OF OCULAR ALBINISM. *RETINA*." The final published version is available at: [<https://doi.org/10.1097/IAE.0000000000001570>]. Uploaded in accordance with the publisher's self-archiving policy. Unauthorized reproduction of this article is prohibited.

Reuse

Items deposited in White Rose Research Online are protected by copyright, with all rights reserved unless indicated otherwise. They may be downloaded and/or printed for private study, or other acts as permitted by national copyright laws. The publisher or other rights holders may allow further reproduction and re-use of the full text version. This is indicated by the licence information on the White Rose Research Online record for the item.

Takedown

If you consider content in White Rose Research Online to be in breach of UK law, please notify us by emailing eprints@whiterose.ac.uk including the URL of the record and the reason for the withdrawal request.

Title: Detailed retinal imaging in carriers of ocular albinism.

Short title: Retinal imaging in Ocular albinism carriers.

Kamron N Khan, PhD, FRCOphth¹⁻³

Emma C Lord, BSc³

Gavin Arno, PhD³

Farrah Islam, FCPS, FRCS²

Keren J Carss, PhD^{5,6}

F Lucy Raymond^{5,7}

Carmel Toomes, PhD³

Manir Ali, PhD³

Chris F Inglehearn, PhD³

Andrew R Webster, MD(Res), FRCOphth^{1,2}

Anthony T Moore, FRCS, FRCOPhth^{1,2,4}

James A Poulter, PhD³

Michel Michaelides, MD(Res), FRCOphth^{1,2}

1. University College London Institute of Ophthalmology, University College London, London, UK.
2. Medical Retina Service, Moorfields Eye Hospital, London, UK.
3. Section of Ophthalmology & Neuroscience, Leeds Institute of Biomedical & Clinical Sciences, St James' University Hospital, Beckett St, Leeds, UK.
4. Ophthalmology Department, University of California San Francisco Medical School, San Francisco, California, USA.
5. NIHR BioResource - Rare Diseases, Cambridge University Hospitals, Cambridge Biomedical Campus, Cambridge, United Kingdom.
6. Department of Haematology, University of Cambridge, NHS Blood and Transplant Centre, Long Road, Cambridge, CB2 OPT, UK
7. Department of Medical Genetics, Cambridge Institute for Medical Research, University of Cambridge, Cambridge, UK

Corresponding authors: Kamron Khan and Michel Michaelides at address 1 above.

Email: medknk@leeds.ac.uk and michel.michaelides@ucl.ac.uk

Grants/ Financial Disclosure: This work was funded by RP Fighting Blindness and Fight for Sight (RP Genome Project GR586). National Institute for Health Research Biomedical Research Centre at Moorfields Eye Hospital National Health Service Foundation Trust and UCL Institute of Ophthalmology (UK; KNK, ATM, MM), Fight For Sight (UK; MM,), Moorfields Eye Hospital Special Trustees (UK; MM), Moorfields Eye Charity (UK; MM), the Foundation Fighting Blindness (FFB, USA; ATM, MM), Retinitis Pigmentosa Fighting Blindness (UK; all authors), Research to Prevent Blindness (unrestricted grant to UCSF Ophthalmology), The National Institute for Health Research England (NIHR) for the NIHR BioResource – Rare Diseases project (RG65966), and the Wellcome Trust (099173/Z/12/Z; ARW, MM). Michel Michaelides is supported by an FFB Career Development Award. This research has been funded/supported by the National Institute for Health Research Rare Diseases Translational Research Collaboration (NIHR RD-TRC). The views expressed are those of the author(s) and not necessarily those of the NHS, the NIHR or the Department of Health.

Proprietary Interest : None

CONFLICT OF INTEREST: No conflicting relationship exists for any of the authors.

KEY WORDS

Ocular albinism

Imaging

Retina

Autofluorescence

Optical coherence tomography

SUMMARY STATEMENT

Ocular albinism may be mistaken for other disorders associated with congenital nystagmus. We identify features of ocular albinism, present in female carriers that will help facilitate an accurate diagnosis.

Abstract

Introduction

Albinism refers to a group of disorders primarily characterised by hypopigmentation. Affected individuals usually manifest both ocular and cutaneous features of the disease, but occasionally hair and skin pigmentation may appear normal. This is the case in ocular albinism, an X chromosome linked disorder resulting from mutation of *GPR143*. Female carriers may be recognised by a "mud-splatter" appearance in the peripheral retina. The macula is thought to be normal however.

Methods

Obligate female carriers of pathogenic *GPR143* alleles were recruited. Molecular confirmation of disease was performed only for atypical cases. Detailed retinal imaging was performed (colour fundus photography, optical coherence tomography (OCT), fundus autofluorescence (FAF)).

Results

8 individuals were ascertained. A novel *GPR143* mutation was identified in one family (p.Gln328Ter). Foveal FAF was subjectively reduced in 6/6 patients imaged. A "tapetal-like" pattern of autofluorescence was visible at the macula in 3/6. Persistence of the inner retinal layers at the fovea was observed in 6/8 females.

Conclusions

Female carriers of ocular albinism manifest sign of RPE mosaicism at the macula as well as the peripheral fundus. A tapetal-like reflex on FAF may be considered the macular correlate of "mud-splatter".

Introduction

Albinism, from the latin, albus (white), represents a range of inherited, congenital disorders of hypomelanosis, typically involving the skin, hair and eyes. The phenotype may be highly variable. In the most extreme cases there is little or no melanin production, whilst milder forms are associated with greater levels of pigmentation.¹ Melanin granules are found in dermal and follicular melanosomes, in addition to melanosomes of the iris, retinal pigment epithelium (RPE) and choroidal stroma.² In most cases, clinical signs are present in all these tissues; these patients are diagnosed as having oculocutaneous albinism (OCA).¹ In the mildest cases, signs may only be identifiable in the eye, as this appears to be the structure most sensitive to pigment dosage. Where the clinical signs are limited to the eye, the term ocular albinism (OA) is used.³ Very rarely, albinism may be associated with additional syndromic features, leading to a diagnosis of Chediak-Higashi (CHS, OMIM 214500) or Hermansky-Pudlak Syndromes (HPS, OMIM 203300, 608233). Other systemic disorders associated with hypomelanosis (also described historically as “partial albinism”) include Griscelli Syndrome (GS, OMIM 414450, 607624), Elejalde disease (ED, OMIM 256710) and Tietz syndrome (OMIM 103500, 156845). These disorders share dysfunction in exocytosis pathways, affecting not only the release of pigment granules but also key components of the clotting cascade from platelets (HPS), lysosomal trafficking (CHS) and cytotoxic granule release from immune cells (GS).

The OA phenotype is associated with both autosomal recessive and X-linked inheritance.^{4,5} It is likely to represent the “tip of the iceberg”, as in addition to major signs that may only be apparent in the eye, subclinical endophenotypes are found in the hair and skin; accordingly it should be thought of as a systemic disease.⁶ The most common form of OA is OA type 1 (OA1, OMIM 300500), transmitted as an X-linked disorder resulting from mutation of *GPR143* (OA1, NM_000273).⁷ *GPR143* encodes a G-protein coupled receptor present in late endosomes, lysosomes, and early stage melanosomes.⁸ Affected males exhibit the classical ocular features of albinism – reduced visual acuity, nystagmus, foveal hypoplasia, iris transillumination defects, reduced fundus pigmentation and chiasmal misrouting, but few if any extra-

ocular signs, particularly in well-pigmented ethnic groups.⁹When carefully compared to unaffected siblings subtle signs of cutaneous hypomelanosis may be evident.⁶The identification of macromelanosomes on skin biopsy confirms that this is indeed a global disorder of melanisation.¹⁰⁻¹²

Females heterozygous for *GPR143* mutations are usually asymptomatic, although signs of carrier status are often present, with a characteristic pattern of depigmentation evident in the iris (transillumination defects) and retinal pigment epithelium (“mud splatter appearance”).^{13, 14}Macular changes however are poorly described. The present work represents a prospective, consecutive case series describing the macular changes present in mothers of male probands with OA.

Methods

Individuals diagnosed as carriers of X-linked OA, and mothers of boys with OA were recruited from the inherited retinal disease (IRD) clinics at Moorfields Eye Hospital, London, UK. Clinical examinations were performed by one of four retina physicians experienced in managing patients with IRD (ATM, MM, ARW, KNK). Participants were assessed using slit lamp biomicroscopy, color fundus photography (CFP), spectral domain optical coherence tomography (OCT) and 488nm wavelength fundus autofluorescence (FAF) (both Spectralis, Heidelberg Engineering, Heidelberg). Visual acuity was measured at 6 meters with a Snellen chart. For atypical cases, molecular genetic confirmation was obtained after whole exome or whole genome sequencing, either as a participant in the NIHR BioResource – Rare Diseases project or an in-house sequencing study (see Supplementary Methods). Segregation of variants identified by whole-exome and whole genome sequencing was performed by polymerase chain reaction and Sanger sequencing using standard protocols.¹⁵ Primers were designed using ExonPrimer¹⁶ and can be found in Supplementary Table 1. As a control group, mothers of children with OCA were also recruited to this study. They also underwent detailed retinal imaging but no genetic investigations were performed. All participants provided informed consent, and research adhered to the principles set out in the Declaration of Helsinki (2013).

Results

Eight females were recruited. Four were ascertained at their affected son's hospital appointment. Two were referred directly, as their optometrist identified pigmentary changes at routine assessment. Two were examined as part of a family survey. In all cases there was at least one additional male relative known to have OA. No families had any affected female family members. The clinical and molecular features are described in Table 1 and Figures 1-3.

In only one case was a reduction in vision recorded, which was lifelong and non-progressive (Case1a). Iris transillumination was present in all female carriers; these defects were clearly visible in the mid to peripheral iris, but were never seen immediately adjacent to the pupillary margin. Nystagmus was never observed. Retinal examination revealed a radial pattern of pigmentation in the peripheral retina consistent with "mud-splatter" (8/8).

Fundus Autofluorescence

The FAF images demonstrated subtle alterations in retinal autofluorescence in all cases where imaging was obtained (6/8). The central zone of hypoautofluorescence was reduced in size, in keeping with reduced luteal pigment (Figures 1a and 2). Immediately adjacent to this an irregular pattern of autofluorescence was observed in the peripheral macula, and in three cases (Cases 1b, 1c and 6) this manifested as a prominent radiating pattern of hyperautofluorescence, in a tapetal-like reflex fashion, not visible by near infrared reflectance imaging (Figure 2) or color fundus photography (Figure 3a). Where visualised, peripheral retinal autofluorescence was characterised by radial patches of relative hypoautofluorescence, corresponding with the observed streaks of relative hyperpigmentation in these regions (Figure 2 and 3c). For one mother the tapetal-like reflex appeared to extend into the peripheral retina (Case 6).

Optical Coherence Tomography

In 6/8 cases, persistence of the inner retinal layers was observed (Figure 1c). Despite this, a change in contour of the third highly reflective OCT line (ellipsoid zone) was

always visible at the foveola, consistent with physiological lengthening of the cone outer segments. The center of the fovea was always avascular. As a surrogate marker of macular pigmentation, the visibility of the sub-foveal sclero-choroidal boundary was recorded (Figure 1c). This junction was clearly visible in 5/8 mothers. Unusually for one mother (Case 1a) this boundary was easily identifiable despite a choroidal thickness of greater than 500 μ m. In 3/8 cases (6 eyes), the boundary between the choroid and sclera was invisible; here the choroidal thickness was estimated to be greater than 350 μ m. Two mothers had a normal foveal contour, without persistence of the inner retinal layers.

Genetics

For two families where there was uncertainty regarding the diagnosis molecular genetic testing was initiated. Retinal examination in Case 4's son was limited by his age and nystagmus velocity, and the results of electrophysiological testing to assess chiasmal misrouting was equivocal. Case 1a's visual acuity was subnormal, and as her full field electroretinogram identified possible rod system dysfunction, a clinical diagnosis of OA carrier remained questionable.

In both cases, after bioinformatic filtering and prioritising genes already implicated in retinal disease¹⁷ only variants in *GPR143* remained as a possible cause of disease. Family 1 (Cases 1a-c) harbored a previously identified pathogenic variant, p.Trp292Gly, sufficient to account for their retinal findings.¹⁸ Testing the son of Case 4 identified a novel null allele (p.Gln328Ter). Sanger sequencing confirmed each variant, and its segregation with the disease phenotype. In both cases the mothers were heterozygous for the mutation.

Control group

In order to determine how specific the above findings are, five mothers of children with OCA were also examined. All were asymptomatic and had normal visual acuity (6/6). No fundus abnormalities were detected with CFP, FAF or OCT. Representative images are shown in Figure 1.

Discussion

In this study we have identified novel clinical features associated with carrier status of ocular albinism— persistence of the retinal ganglion cell layer at the fovea, reduced foveal hypoa autofluorescence, and irregular peripheral macular autofluorescence. In this study these features were present in the majority of cases, and almost always associated with excellent vision. As recognizing rare disorders may be difficult, these easy to detect clinical features should help facilitate a prompt and accurate diagnosis, both for carriers of OA and by inference their affected male children.

Hypomelanosis is thought to occur as a result of random X-chromosome inactivation. Unlike the variable asymmetrical scattered mosaic appearance observed in carriers of *CHM* (choroideremia) and *RPGR/RP2* (rod-cone and cone-rod dystrophy) mutations, stereotyped pigmentary changes occur in carriers of X-linked OA— radial streaks of relative hyperpigmentation seen adjacent to lines of hypopigmentation, commonly referred to as “mud-splatter”.^{14, 19} This reproducible finding however is seemingly not in keeping with a random event. As X-chromosome inactivation occurs as an independent event in each cell of the developing blastocyst, a continuous streak of hypopigmented cells should not occur by chance, as this would require a consecutive series of hundreds of adjacent cells to each inactivate the same X-chromosome.¹⁹ A more parsimonious explanation is that all RPE cells in a streak of hypopigmentation derive from a common RPE progenitor, with the same X-chromosome inactivated. The pattern seen may therefore be an observation of the migration pattern of developing RPE cells, preprogrammed to either express the mutant or wild-type protein. This phenotype may be thought of as the ocular equivalent of Blaschko’s lines, alternating swirls of hyperpigmented and normally pigmented skin cells which occur in a range of dermatological conditions.²⁰

To date macular changes have not been described in carriers of OA, as “mud splatter” is considered a phenomenon of the peripheral retina. Even in the most extreme cases of albinism the macula rarely appears depigmented, suggesting that either these cells are relatively spared or that other pigmented structures are well preserved. Melanin granules reside within the RPE and choroidal stroma. In their

absence, the fundus has a blonde hue, representing the color of light reflected from the sclera, filtered by a depigmented RPE and retina. Macula anatomy differs from that in the peripheral retina, with a greater density of RPE cells and a thicker choroid, both factors that would result in significant residual pigmentation. The choroid so contains significant numbers of erythrocytes, adding further color. Lastly, luteal pigments, lutein and zeaxanthin are stored here too. A reduction in melanin content will therefore remain relatively disguised at the macula and more apparent in the periphery where the retina, RPE and choroid are thinnest.

Using multimodal imaging this study has identified three novel characteristic traits identified in female carriers of OA. Firstly, using 488nm FAF imaging, linear streaks, described as a “tapetal-like” reflex, are visible at the macula of two sisters (Cases 1b and 1c) and a third unrelated mother (Case6). This finding is thought to be unique to female carriers of X-linked retinitis pigmentosa (XLRP), however no variants in *RPGR* or *RP2* were identified after whole exome sequencing (Cases 1b and 1c). These individuals would therefore represent the first report of a tapetal-like reflex in association with OA, a finding that may represent the macular correlate of “mud-splatter”(Figure 2). As this appearance is more commonly seen in patients with primary photoreceptor disease it may seem curious as to why the migratory patterns of embryonic RPE cells influence the expression of a photoreceptor disease. One explanation may relate to the interaction between these cells, as randomly distributed dysfunctional photoreceptors may only influence susceptible clones of RPE cells, themselves distributed in a non-random, radial manner.

Secondly, the central zone of physiological hypoautofluorescence appears to be reduced in size in comparison to healthy controls (Figure 1a). Although normal macular autofluorescence may show significant inter-individual variation, thought to relate to the distribution of macular pigments, all cases tested (10 eyes) shared the phenotype of a single small zone of reduced autofluorescence. Taken in isolation this may have been a chance occurrence, however in conjunction with other structural changes this is likely to be a further biomarker of carrier status.

Thirdly, 6/8 female carriers demonstrated subtle persistence of the retinal ganglion cell (RGC) layer at the fovea, without clinical evidence of foveal vascularization or loss of acuity. This suggests that maturation of the inner retina may be the structure most sensitive to loss of melanin. In 2/8 cases where RGCs were absent from the fovea, the posterior choroidal boundary was also not visible, perhaps suggesting that eyes with more melanin are less likely to show signs of foveal immaturity. As the fovea may sustain excellent acuity even when vascularized, one may now impute a hierarchy for sensitivity to melanisation. Subtle loss of pigment results in foveal RGC persistence, greater loss of melanin results in RGC persistence alongside foveal vascularity (but good vision), and the most severe end of the spectrum is a “full house” of signs – persistence of the inner retinal layers/absence of a foveal pit, foveal vascularization, and central macular dysfunction (loss of acuity). Heterozygosity for OA variants may therefore alter macular melanisation minimally, associated with clinical findings of normal acuity and macular anatomy (1/8 here), whilst in others it may be associated with subtle persistence of foveal RGC (6/8 cases). Rarely, in more extreme cases (1/8 here), foveal hypoplasia and reduced visual acuity may be noted.

A detailed eye examination is often extremely helpful when determining the inheritance pattern for genetic disorders, particularly those inherited in an X-linked manner. Clinical findings of carrier status have been reported both for eye disease as well as systemic disorders (Table 2). Carrier status may not always be associated with overt clinical signs, as mothers of boys with X-linked retinoschisis (XLR5; OMIM 312700) and congenital stationary night blindness (OMIM 310500, 300071) have a normal retinal appearance. It may be however that more sensitive forms of testing reveal subtle signs of dysfunction (e.g. Frumke effect detected by psychophysical testing in XLR5 carriers).²¹ To date clinical findings in female carriers of OA have been variable, as most reports suggest that female carriers have no OCT or FAF abnormalities, however others describe significant changes.²²⁻²⁴ This discrepancy may in part relate to uncertainty regarding the pattern of inheritance, as autosomal recessive disease may masquerade as XLOA in the absence of a molecular diagnosis.²⁵ The inability to identify *GPR143* mutations similarly doesn't exclude this

as a cause of disease, as the screening technique will determine the detection sensitivity which varies between 35-90%.^{18, 26-29} It appears less likely that novel genes are responsible for this low sensitivity, as linkage analysis in pedigrees with no identifiable pathogenic variants in *GPR143* still maps the disease to this locus.^{18, 26, 29} Unsurprisingly, intronic variants in *GPR143* have now been associated with disease.³⁰ Other potential reasons for the variation in the clinical findings not controlled for in this study are chromosomal anomalies (Turner syndrome or variations thereof) and skewed X chromosome inactivation.

In summary, multimodal imaging in female carriers of OA demonstrates abnormalities of macular as well as peripheral retinal development. These patterns are likely to occur as a result of early X-chromosome inactivation, where clones of RPE cells all express the same X-chromosome. These novel findings will provide additional diagnostic clues for clinicians, and allow vision researchers to better understand the *in vivo* migration of human RPE cells.

References

1. David CV. Oculocutaneous albinism. *Cutis* 2013; 91:E1-4.
2. Yamaguchi Y and Hearing VJ. Melanocytes and their diseases. *Cold Spring Harbor perspectives in medicine* 2014; 4.
3. Montoliu L et al. Increasing the complexity: new genes and new types of albinism. *Pigment Cell Melanoma Res* 2014; 27:11-18.
4. Oetting WS. New insights into ocular albinism type 1 (OA1): Mutations and polymorphisms of the OA1 gene. *Hum Mutat* 2002; 19:85-92.
5. Fukai K et al. Autosomal recessive ocular albinism associated with a functionally significant tyrosinase gene polymorphism. *Nat Genet* 1995; 9:92-95.
6. Shen B et al. Ocular albinism type 1: more than meets the eye. *Pigment Cell Res* 2001; 14:243-248.
7. Bassi MT et al. Cloning of the gene for ocular albinism type 1 from the distal short arm of the X chromosome. *Nat Genet* 1995; 10:13-19.
8. Schiaffino MV et al. Ocular albinism: evidence for a defect in an intracellular signal transduction system. *Nat Genet* 1999; 23:108-112.
9. Charles SJ et al. Clinical features of affected males with X linked ocular albinism. *Br J Ophthalmol* 1993; 77:222-227.
10. O'Donnell FE, Jr. et al. X-linked ocular albinism. An oculocutaneous macromelanosomal disorder. *Arch Ophthalmol* 1976; 94:1883-1892.
11. Garner A and Jay BS. Macromelanosomes in X-linked ocular albinism. *Histopathology* 1980; 4:243-254.
12. Yoshiike T et al. Macromelanosomes in X-linked ocular albinism (XLOA). *Acta Derm Venereol* 1985; 65:66-69.
13. Costa DL et al. X-linked ocular albinism: fundus of a heterozygous female. *Retina* 2003; 23:410-411.
14. Charles SJ et al. Genetic counselling in X-linked ocular albinism: clinical features of the carrier state. *Eye (Lond)* 1992; 6 (Pt 1):75-79.
15. Townson SM et al. A purified ferredoxin from *Giardia duodenalis*. *Eur J Biochem* 1994; 220:439-446.
16. HelmHoltz Centre Munich IOHG. About ExonPrimer. in Strom TM ed.
17. The University of Texas. School of Public Health. 2012.

18. Schiaffino MV et al. Analysis of the OA1 gene reveals mutations in only one-third of patients with X-linked ocular albinism. *Hum Mol Genet* 1995; 4:2319-2325.
19. Wuthisiri W et al. Lyonization in ophthalmology. *Curr Opin Ophthalmol* 2013; 24:389-397.
20. Blaschko A. Die Nervenverteilung in der Haut in ihre Beziehung zu den Erkrankungen der Haut. 1901.
21. Arden GB et al. Detection of the carrier state of X-linked retinoschisis. *Am J Ophthalmol* 1988; 105:590-595.
22. Sepulveda-Vazquez HE et al. Macular optical coherence tomography findings and GPR143 mutations in patients with ocular albinism. *Int Ophthalmol* 2014; 34:1075-1081.
23. Rudolph G et al. X-linked ocular albinism (Nettleship-Falls): a novel 29-bp deletion in exon 1. Carrier detection by ophthalmic examination and DNA analysis. *Graefes Arch Clin Exp Ophthalmol* 2001; 239:167-172.
24. Pearce WG, Johnson GJ and Gillan JG. Nystagmus in a female carrier of ocular albinism. *J Med Genet* 1972; 9:126-129.
25. Hutton SM and Spritz RA. A comprehensive genetic study of autosomal recessive ocular albinism in Caucasian patients. *Invest Ophthalmol Vis Sci* 2008; 49:868-872.
26. Rosenberg T and Schwartz M. X-linked ocular albinism: prevalence and mutations--a national study. *Eur J Hum Genet* 1998; 6:570-577.
27. Schnur RE et al. OA1 mutations and deletions in X-linked ocular albinism. *Am J Hum Genet* 1998; 62:800-809.
28. Bassi MT et al. Diverse prevalence of large deletions within the OA1 gene in ocular albinism type 1 patients from Europe and North America. *Hum Genet* 2001; 108:51-54.
29. Camand O et al. Mutational analysis of the OA1 gene in ocular albinism. *Ophthalmic Genet* 2003; 24:167-173.
30. Naruto T et al. Deep intronic GPR143 mutation in a Japanese family with ocular albinism. *Scientific reports* 2015; 5:11334.

Figure Legends

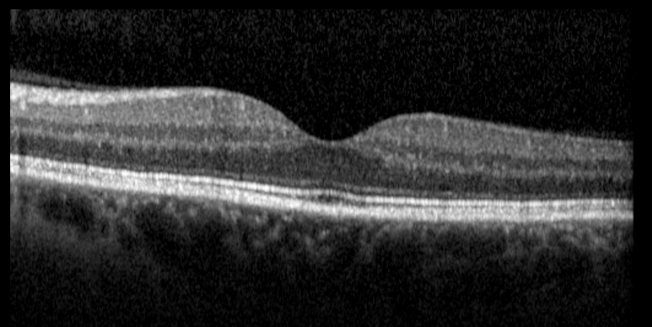
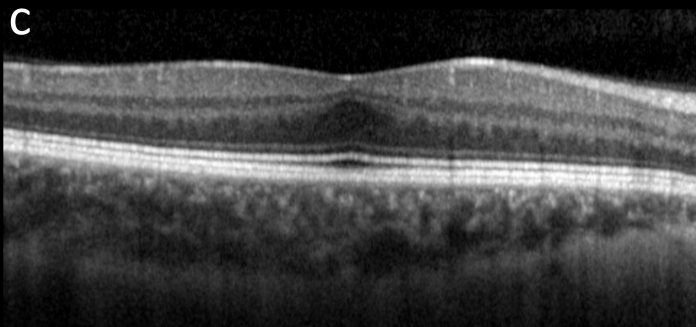
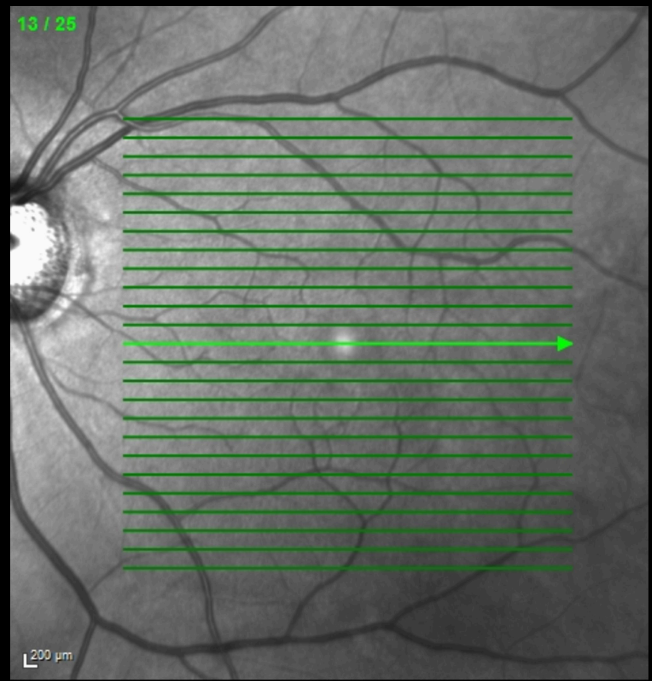
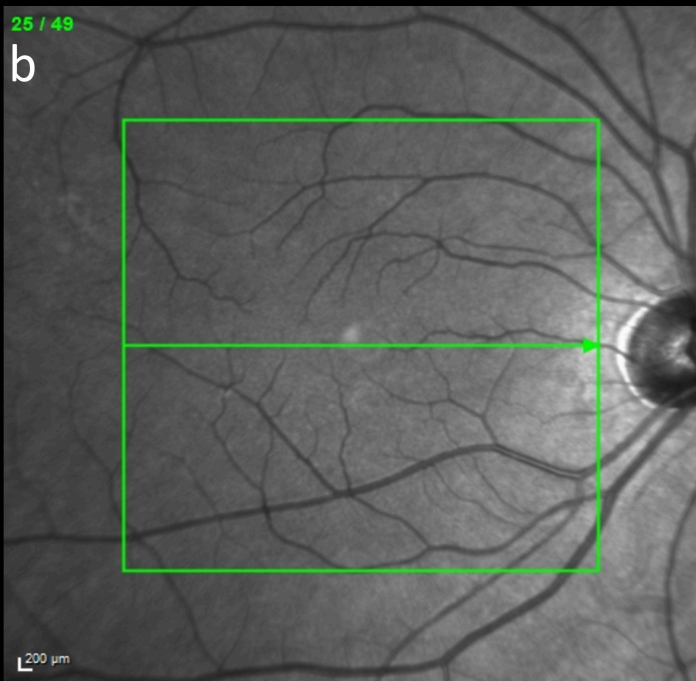
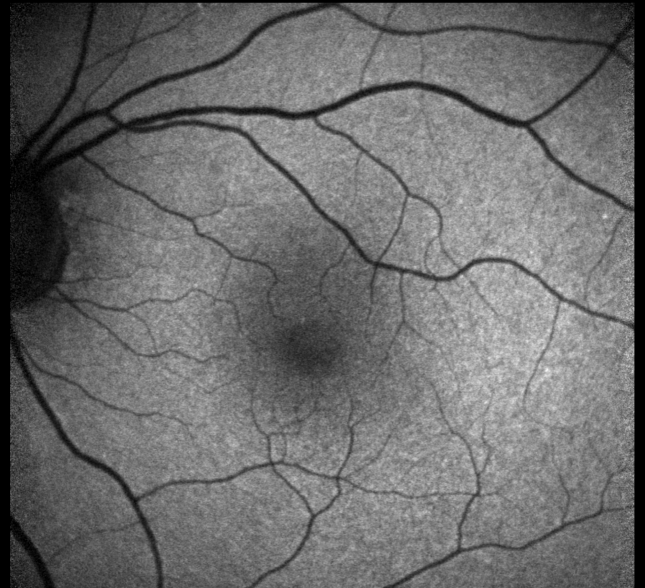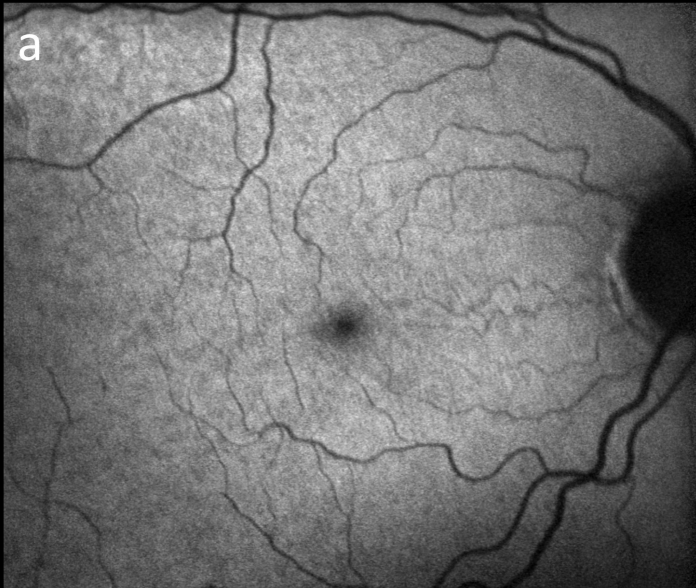Figure 1. Typical retinal changes in female carriers of ocular albinism (OA) and oculocutaneous albinism (OCA) as detected by multimodal imaging. (a) 488nm fundus autofluorescence demonstrating a smaller than normal zone of physiological hypoautofluorescence in Case 4, (b) near infrared reflectance appears normal, whilst (c) optical coherence tomography scans through the fovea identify persistence of the inner retinal layers in Case 4. Similar changes were not evident in five obligate female carriers of (recessive) OCA alleles.

Figure 2. Multimodal macular imaging in three female carriers of ocular albinism. For each patient images of the right and left eyes are shown, with 488nm fundus autofluorescence (FAF) (top) and near infrared reflectance (NIR-R) (bottom). These three individuals have a radially distributed bright reflex, centered on the fovea, apparent on FAF but not NIR-R imaging. For Case 6, where 55° widefield imaging is available, this reflex is seen to extend into the peripheral retina.

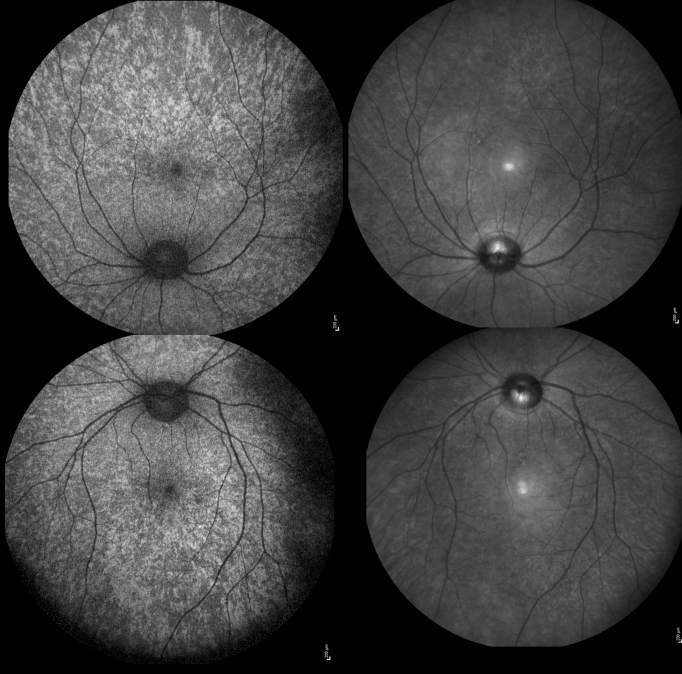
Figure 3. Widefield imaging in female carriers of ocular albinism. (a) A montage of color fundus photographs from Case 1b demonstrating absence of the tapetal-like reflex seen in Figure 2, and peripheral streaks of hypopigmentation. (b) Optos widefield pseudocolor and (c) green laser autofluorescence imaging in Case 6 similarly identifies peripheral streaks of reduced pigmentation and increased autofluorescence signal.

OA Carrier Female

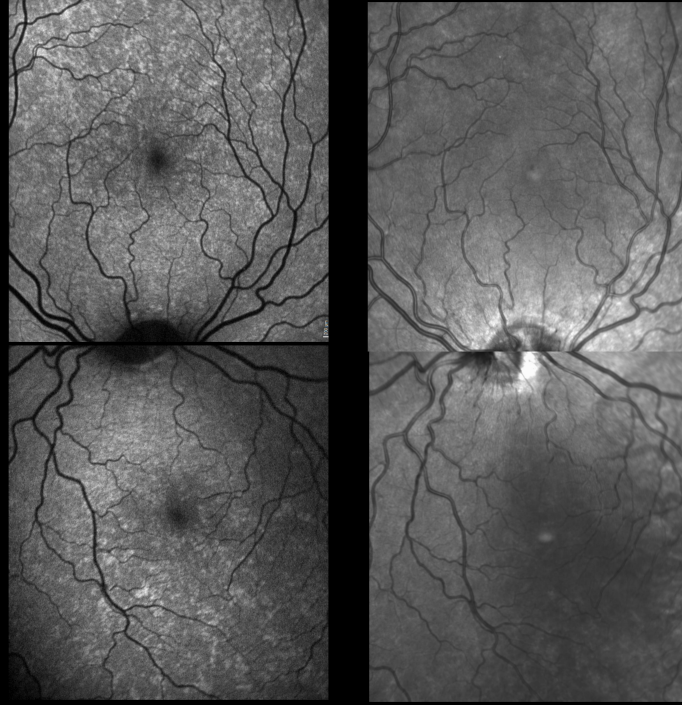
OCA carrier Female



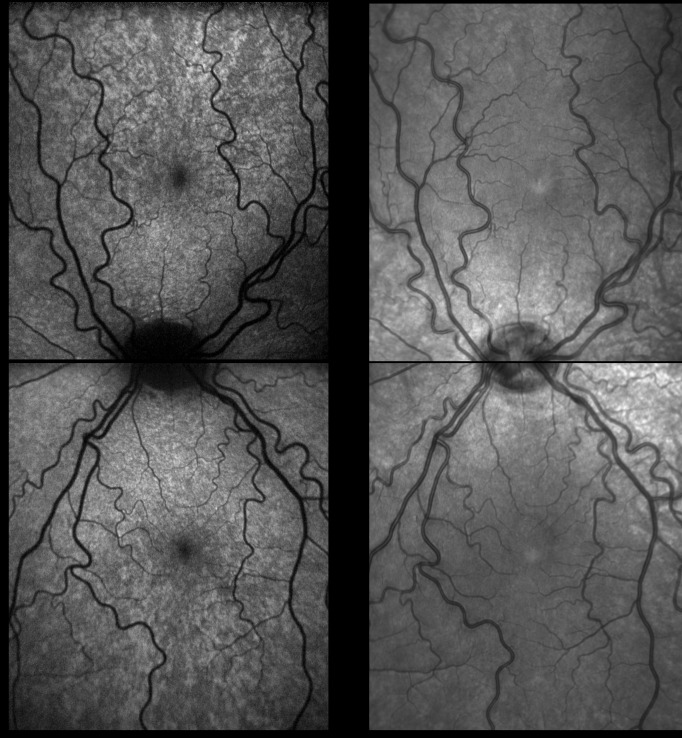
Case 6



Case 1c



Case 1b



FAF

NIR-R