




Contents lists available at [ScienceDirect](http://www.sciencedirect.com)

## Translational Research in Anatomy

journal homepage: <http://www.journals.elsevier.com/translational-research-in-anatomy>



# The structure and function of the cervix during pregnancy



James P. Nott <sup>a</sup>, Elizabeth A. Bonney <sup>b</sup>, James D. Pickering <sup>c</sup>, Nigel A.B. Simpson <sup>a,\*</sup>

<sup>a</sup> Division of Women's and Children's Health, School of Medicine, University of Leeds, Leeds, UK

<sup>b</sup> Leeds Teaching Hospitals NHS Trust, Leeds, UK

<sup>c</sup> Division of Anatomy, School of Medicine, University of Leeds, Leeds, UK

### ARTICLE INFO

#### Article history:

Received 8 December 2015

Received in revised form

25 January 2016

Accepted 29 February 2016

Available online 2 March 2016

#### Keywords:

Cervix

Pregnancy

Preterm birth

Cervical weakness

### ABSTRACT

The structure of the cervix is integral to the maintenance of pregnancy, keeping the developing baby *in utero* and forming a barrier to the ascent of microorganisms from the vagina. Weakness of the cervix may lead to deficiency of this barrier and is associated with subsequent preterm birth. The underlying cause of this structural weakness is poorly understood. In this paper we review the structure and function of the cervix before and during pregnancy. The causes of mechanical failure of the cervix during pregnancy are described, with a specific focus on the internal cervical os. We highlight the role of the internal cervical os in causing preterm birth and discuss research techniques that may provide further insight into its function during pregnancy. It is hoped that clinical translation of this knowledge will enable the early and appropriate identification of women who will benefit from strategies to reinforce the internal os and so reduce the incidence of preterm birth.

© 2016 University of Leeds. Published by Elsevier GmbH. This is an open access article under the CC BY-NC-ND license (<http://creativecommons.org/licenses/by-nc-nd/4.0/>).

### Contents

1. Introduction .....	1
2. Structure of the cervix .....	2
2.1. Gross anatomy .....	2
2.2. Microanatomy .....	2
2.2.1. Epithelium .....	2
2.2.2. Stroma .....	2
3. Function of the cervix .....	3
3.1. Cyclical changes and the structure of the cervix .....	3
3.2. Cervical mucus production and secretion .....	3
4. Changes during pregnancy .....	3
5. Changes during labour .....	4
6. Preterm birth .....	4
7. Future research and the internal cervical os .....	5
8. Conclusion .....	6
Acknowledgements .....	6
References .....	6

## 1. Introduction

The cervix is integral to conception, the maintenance of pregnancy, and timely delivery of the baby. Throughout gestation the cervix must remain closed despite multiple forces acting upon it [1]. This enables it to act as a barrier to the ascent of vaginal

\* Corresponding author. Division of Women's and Children's Health, Level 9, Worsley Building, School of Medicine, University of Leeds, Clarendon Way, Leeds, LS2 9NL, UK.

E-mail address: [n.a.b.simpson@leeds.ac.uk](mailto:n.a.b.simpson@leeds.ac.uk) (N.A.B. Simpson).

microorganisms and to retain the growing fetus within the uterus. At term and during labour, the cervix must soften, shorten and dilate to allow for the baby's passage. Inherited and acquired weakness of the cervix may compromise its function and increase the risk of preterm birth (PTB)<sup>1</sup> [2]. The underlying anatomy of the cervix responsible for its effectiveness is poorly understood although its deficiency may result in premature birth.

This review will describe the structure of the normal cervix and how this allows it to fulfil its primary function during pregnancy. The causes of mechanical failure of the cervix will be described, with a specific focus on the internal cervical os. Finally, current and future research directions in this area will be outlined.

## 2. Structure of the cervix

### 2.1. Gross anatomy

The cervix is a firm, cylindrical structure situated at the lower pole of the uterine corpus. The length of a normal adult non-pregnant cervix is approximately 25 mm, with an anteroposterior diameter ranging between 20 and 25 mm and a transverse diameter of 25–30 mm, although considerable variations occur due to age, parity and stage of menstrual cycle [3–5]. The cervix is divided into two portions that lie above and below the vaginal reflection, the portio supravaginalis and portio vaginalis respectively. Outside of pregnancy the cervical canal is collapsed, firm, and fusiform in shape. It ensures communication between the cavity of the corpus and the lumen of the vagina, and is bounded by the internal and external os.

The cervix is located within the 'true pelvis', posterior to the bladder base and directly anterior to the rectum. Separating the bladder from the upper portion of the cervix is the perimetrium, which is reflected on to the base of the bladder to form the vesico-uterine pouch. A lateral extension of this tissue passes towards the pelvic walls and encloses a number of important structures including the uterine vessels and ureters, surrounded by areolar tissues. Posteriorly, the rectouterine pouch (of Douglas) is formed as a result of the peritoneal reflection from the cervix inferiorly to the posterior vaginal fornix and onto the rectum.

The cervix is held in place by paired ligaments on either side: the uterosacral and cardinal (transverse cervical) ligaments. The uterosacral ligaments run from the posterior and lateral supravaginal portions of the cervix to the middle three sacral vertebrae [5]. Near the most distal attachment at the cervix, the uterosacral ligaments interlace with their respective cardinal transverse ligaments for approximately 2 cm, before running to their proximal attachments [6]. It is thought that the uterosacral ligaments help to maintain the uterus in its typically anteverted state. The cardinal ligaments are the principal supports of the cervix. The attachments and positioning of the cardinal ligaments have been researched extensively, with great variation being observed. Although there remains controversy over whether these structures represent true ligaments or fascial condensations, a recent literature review has identified a variety of attachment sites on or running towards the pelvic side wall, including both iliac fossae, ischial spines, broad ligaments, and internal iliac vessels [7].

The cervix receives its principal blood supply from branches of the uterine artery; vaginal arteries arising from the internal iliac arteries may also contribute [8]. The vascular anatomy at the uterocervical junction of the cervix has been described as having four distinct regions: an outer region containing larger vessels, an arteriole and venule region, an endocervical capillary region and a

pericanalar zone of small veins and capillaries [9,10]. This complex arrangement is thought to exist throughout the cervix, although variations in vessel size and vessel course are noted between the portio supravaginalis and portio vaginalis [10]. Whether or not the density of this vascular investment provides significant structural support to the upper cervix is not known.

### 2.2. Microanatomy

#### 2.2.1. Epithelium

The endocervical canal is lined by a single folded layer of mucus-secreting columnar epithelium. This layer extends towards the squamous epithelium of the vagina to form the squamocolumnar junction, an anatomical location susceptible to malignant change [11]. Histologically, the epithelial cells of the endocervical canal appear tall and slender, and are closely adhered to each other. The round or oval nuclei of these cells are found between the middle and basal thirds of the cell [5].

The cervix is without glands. Instead, the infoldings of the columnar epithelium create extensive crypt-like structures that secrete cervical mucus and act as storage sites for spermatozoa following intercourse [12]. Squamous metaplastic processes often occlude these clefts, manifesting clinically as Nabothian follicles [13].

#### 2.2.2. Stroma

The components of the subepithelial stroma of the cervix have been well documented. The firmness of the cervix is a result of the presence of collagen (70% type I and 30% type III), which is the predominant protein of its extracellular matrix. Collagen and the associated ground substance account for up to 80% of the sub-epithelial stroma [14,15]. It is thought that the directionality of the collagen fibres may determine their ability to withstand forces encountered in pregnancy: circumferentially around the cervical canal to prevent dilation of the cervix [16,17], and longitudinally to resist those associated with cervical effacement [18].

The proportion of smooth muscle is variable. Estimates typically suggest smooth muscle accounts for 10–15% of the cervical stroma, but estimates from 0 to 45% have also been observed [14,15,19]. The distribution of smooth muscle is scattered at random throughout the stroma, with very few bundles being formed. It has also been assumed from these studies that the cervical smooth muscle is unlikely to be functional due to fibre immaturity and fibre positioning within densely tangled collagen [19].

Elastin has consistently been reported as comprising a small percentage of the stromal substance [20]. The majority of elastin

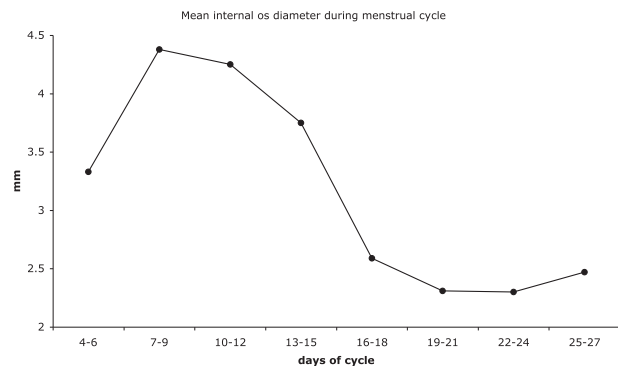


Fig. 1. A graph displaying the changes in the mean diameter of the internal os throughout the menstrual cycle as documented in Asplund's (1952) series of radiographic studies [4].

<sup>1</sup> PTB-preterm birth.

fibres are found in vessel walls, but a few are scattered throughout the cervical stroma [14]. In some studies, the proportion of elastin was observed to be greater (0.9–1.6%) when specific staining or biochemical techniques were used [21,22]. In these studies, elastin was seen to be oriented from the external os to the periphery, whereby fibres extended as a band towards the internal os. At the internal os the elastic fibres became sparse, corresponding to where the greatest amount of smooth muscle was found [23]. Elastin is presumed to be important in cervical remodelling during and after pregnancy [21,23,24].

### 3. Function of the cervix

#### 3.1. Cyclical changes and the structure of the cervix

The cervix demonstrates a considerable amount of anatomic (and physiologic) variation throughout the menstrual cycle. This is required to either promote or prevent the passage of spermatozoa and also to facilitate endometrial shedding.

Cyclical changes of the diameter of the internal cervical os have been characterised. In Asplund's classic series of radiographic studies [4], a modified hystero-graphic technique was used to record its variation throughout the phases of the menstrual cycle. It was observed that in the menstrual and proliferative phases the cervical canal was at its widest, and the cervical mucosa more serrated, when compared to the secretory phase (Fig. 1) [4]. This has been subsequently supported and further quantified in magnetic resonance imaging (MRI) studies in which the mean width of the cervical canal was 4.5 mm in the follicular phase and 3.8 mm in the secretory phase of the menstrual cycle [25]. This study also demonstrated that the overall width and length of the cervix were greatest in the follicular phase of the menstrual cycle [25]. In a separate radiographic study that sought to determine the site of the isthmus, it was observed that the internal os appeared tightly closed during the luteal phase of the ovarian cycle and appeared to relax before the onset of menstruation [26]. Using a technique termed 'direct hystero-graphy,' the author observed that lipiodol injected into the uterine cavity was retained between one to three hours in the follicular phase, between four to eight hours in the luteal phase, and less than 30 min two days prior to menstruation [26]. These results indicate that the cervix is able to narrow and widen at the junction between the corpus and the cervix.

#### 3.2. Cervical mucus production and secretion

The main product of the human cervix is cervical mucus [27].

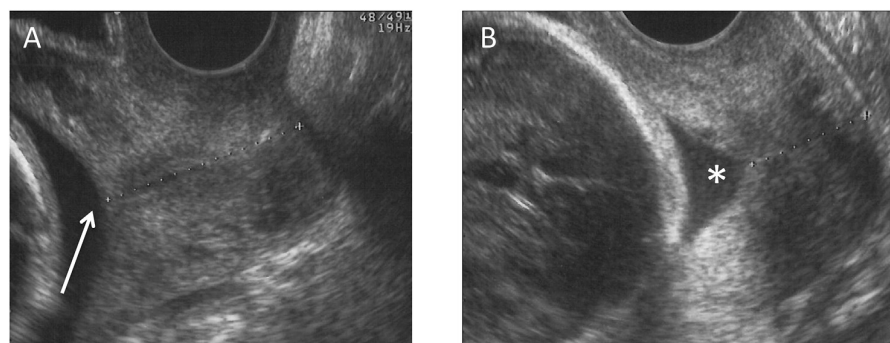
The manufacture and secretion of cervical mucus by the cervical columnar cells throughout the menstrual cycle is regulated by oestrogen and progesterone [28]. During ovulation the mucus produced has a stretchy and stringy consistency (*spinnbarkeit*), presumably facilitating the migration of sperm by providing an environment that is optimal for ascent, storage and survival of sperm [28]. Following ovulation and conception, the secretion of progesterone by the corpus luteum predominates in the second half of the cycle. The mucus reduces in fluidity and volume, becoming tacky and viscous, presumably discouraging spermatozoal and microbial ascent into the uterus.

### 4. Changes during pregnancy

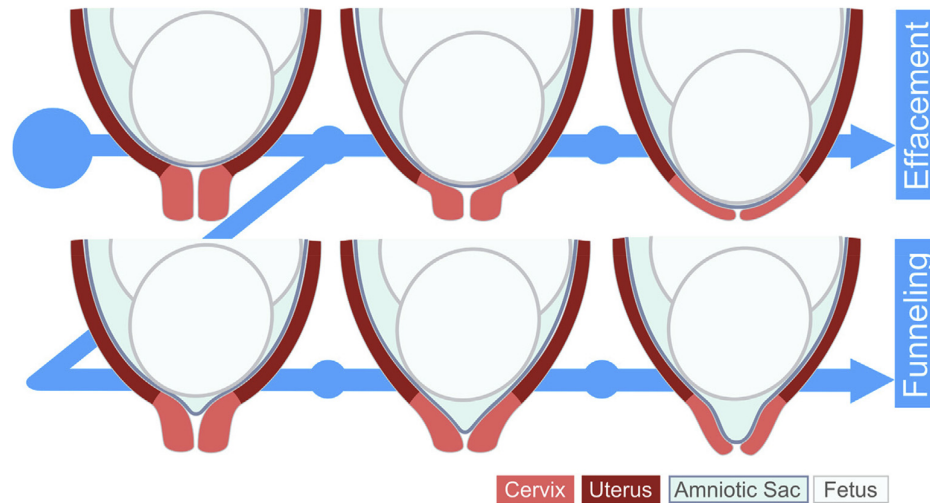
The function of the cervix from this moment is to retain and protect the growing conceptus. An effective barrier is primarily accomplished through retaining a sufficient length of closed cervix within which the mucus plug can deter ascent of microbes from the lower genital tract [29]. This is aided by maintaining sufficient strength at the level of the internal os to discourage descent of the fetal membranes and conceptus down the cervical canal, which may shorten this barrier and/or dislodge the mucus plug.

The appearances of the cervix throughout pregnancy have been well documented using transvaginal ultrasound imaging. In normal pregnancy, sonographic measurements show that cervical length demonstrates a bell-shaped distribution, like most biologic variables [30], with the majority of women maintaining a cervical length between 30 and 40 mm throughout pregnancy (Fig. 2A) [31]. Pregnancies in whom the cervical length is less than 20 mm are more likely to deliver preterm (before 37 completed weeks of pregnancy, Fig. 2B). Strategies used to prevent this include reinforcement of the short or weak cervix by inserting an encircling suture [32].

Maintenance of length may also be assisted in normal pregnancy by displacement of the internal cervical os, which has also been observed using ultrasound imaging. In a study looking at singleton and twin pregnancies, two transperineal scans were performed 12 weeks apart (20 and 32 weeks). Both scans were registered using the pubic symphysis as a fixed point of reference to allow for the internal os to be tracked. Similar displacement of the internal os was observed in both groups (21 mm vs. 20 mm), however the direction of displacement was anteriorly in singletons and inferiorly in twin pregnancies. Furthermore, cervical shortening was only associated with inferior displacement [33]. It was therefore speculated that the increased inferior displacement seen in twin pregnancies was as a result of increased uterine weight, leading to the stretching of the cervical support structures and increased uterine distension, which



**Fig. 2.** Transvaginal ultrasound scan images displaying changes in the appearance of the cervix in the mid-trimester of pregnancy. (A) Scan at 19 weeks gestation demonstrating normal views of a closed internal os (arrow) and cervical length of 37 mm. The dotted line indicates the course of the cervical canal. The mother was receiving progesterone injections due to previous midtrimester loss at 19 weeks. The baby was delivered at term. (B) Scan at 23 weeks gestation showing collapse of internal os (asterisk) and fetal membranes protruding into the upper cervical canal and consequent shortening of the cervical barrier to 19 mm. The mother had had previous deliveries at 33 and 35 weeks.



**Fig. 3.** A comparison between normal and pathologic cervical remodeling: The upper panel shows cervical effacement, a progressive and concurrent change in the compliance and the length of the cervix that occurs as a consequence of alterations in collagen alignment (due to the actions of collagenases and elastases) and engagement/descent of the fetal head within the lower uterine segment. The lower panel illustrates cervical funneling, whereby there is premature protrusion of the fetal membranes into the upper cervical canal secondary to functional weakness of the internal os, resulting in pathologic shortening of the cervix. Published with permission, copyright Elsevier [1].

in turn might accelerate physiologic cervical changes. The use of physician-inserted cervical pessaries in pregnancies at risk of pre-term birth is hypothesised to accentuate anterior displacement and may explain their efficacy [34].

The three-dimensional (3D) anatomy of the cervix during pregnancy is poorly understood [35], and it is only in the last ten years that the structural changes that occur have been studied. The preferred methods of investigation include magnetic resonance imaging (MRI) [36,37] and 3D ultrasonography [38,39], with reconstructions based on these anatomic data and others derived from the known physical properties of the subepithelial stromal components. Although there are some limitations with the methods, these are some of the first studies that have considered the three-dimensional cervical changes that occur during pregnancy. In one study, women who were undergoing MRI for suspected fetal abnormalities were thereby able to provide morphologic data regarding uterine structural changes. Images were obtained at 17–36 weeks using a 1.5T fast-spin echo proton density-weighted pulse sequence. It was observed that as gestational age increased, both the cross-sectional area of cervical canal and cervical stroma increased by around one-third. It was suggested that the changes could be attributed to a decrease in tensile strength of the stroma due to collagenolysis and decreased collagen content, with the increase in stromal area being a consequence of collagen network relaxation [36]. This increase in tissue volume may help keep the cervix closed during normal pregnancy whilst its mechanical properties change [40].

In a later study, using a modified pulse sequence, a comparison was made in a sample of 14 women between the three-dimensional anatomy of uterus and cervix in the second and third trimesters. It was observed that the changes in cervical anatomy between the two time periods were as a result of an increase in the volume of the lower amniotic cavity. This increase in volume was seen to modify the anatomy at the isthmus, leading to a shorter cervix as pregnancy progressed into the final trimester [37].

## 5. Changes during labour

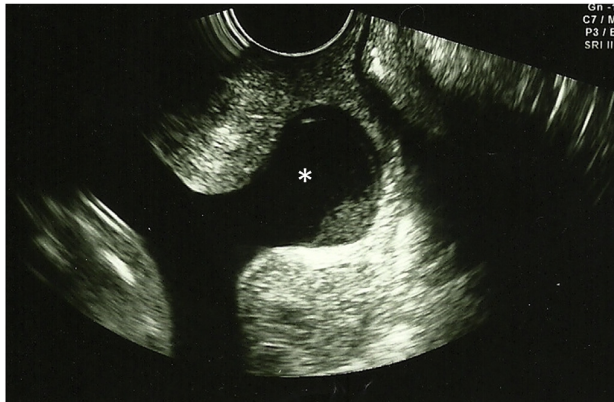
As labour approaches the cervix must undergo a dramatic

process of remodelling to allow for passage of the fetus (Fig. 3). Remodelling can be subdivided into four overlapping phases: softening, ripening, dilation and postpartum restoration [41]. The process as a whole is as a consequence of enzymatic processes that lead to alterations in collagen alignment and organization [40], resulting in both structural and mechanical change.

Throughout the latter stages of pregnancy, the cervix undergoes this process as a result of increased collagenase activity. Labour onset at term is governed by fetal and placental endocrine signaling, which triggers an inflammatory cascade of cytokines, prostaglandins, and oxytocin release. In response to uterine contractions, the already softened cervix begins to efface and dilate as a result of the pressure being exerted either by the fetal membranes and/or the presenting part. Cervical effacement refers to the shortening of the cervical canal, in which it diminishes from around 2 cm to an effaced circular orifice. The process is thought to take place from above downwards, in which the muscle fibres located at the internal cervical os are ‘taken up’ to become an anatomic and physiologic part of the lower uterine segment. To allow for the passage of the fetal head, the cervix must completely dilate and efface such that no element can be palpable at vaginal examination by the beginning of the expulsive phase of the second stage.

## 6. Preterm birth

Preterm birth affects 15 million pregnancies annually and is the leading cause of neonatal morbidity as well as the second leading cause of death in children under five years due to the complications that ensue [42]. The normal gestational length (‘term’) occurs within a five-week window between 37 and 42 weeks from the beginning of the last menstrual period. A baby is considered to have been born ‘preterm’ if they are delivered before 37 completed weeks, and this can be further subdivided depending on gestational age: extremely preterm (<28 weeks), very preterm (28–32 weeks) and moderate to late preterm (32–37 weeks). There is an inverse correlation between gestational age of the neonate and the severity of the adverse outcomes [43]. Even though significant advances have been made in neonatal care which have principally improved survival [44], long-term morbidity is still common amongst



**Fig. 4.** Transvaginal ultrasound scan at 22 weeks gestation demonstrating weakness and collapse of the internal os with subsequent protrusion of fetal membranes (asterisk) into the upper cervical canal. The mother had had previous excisional cervical surgery for precancerous change. The length of closed cervix was 9 mm at the time of the scan and consequently a cervical stitch (cerclage) was inserted in order to extend gestation. The membranes ruptured and delivery of a live baby subsequently occurred at 31 weeks of pregnancy.

individuals born preterm [45].

Preterm birth may be *indicated* if mother or baby are felt to be at risk of further prolongation of the pregnancy, or *spontaneous* when delivery occurs without initiation. The latter can be linked to one of several pathways: 1) variations in the size and shape of the uterus (as seen in Müllerian variants), 2) deficient placentation, 3) altered microbial flora within the lower genital tract, 4) systemic infection/inflammation, and 5) reduction in length or strength of the cervix, known as ‘cervical insufficiency’. The first four are beyond the scope of this review and the reader is referred elsewhere for further insights into these associations. We shall, however, consider the cervix.

A reduction in the length of the cervix will be associated with increased bacterial ascent into the lower pole of the uterus, with concomitant response of maternal and/or fetal origin and the release of inflammatory mediators as described above, leading to preterm parturition. A short cervix may be inherited or be a consequence of surgery carried out to remove precancerous epithelial cells at the external os and distal canal. Weakness of the cervix leads to herniation of the amniotic sac down the cervical canal (Fig. 4), effectively shortening the barrier and also promoting microbial ascent and its sequelae. Women who have undergone forceful dilatation of the cervix to facilitate, for example, surgical termination of pregnancy, are also known to have an increased risk of preterm birth.

The term ‘cervical insufficiency’ is commonly used to describe the pathway whereby reduction in strength or length of the cervix leads to early delivery, especially when very preterm or where loss has occurred within the mid-trimester. It lacks a consistent definition, but is classically described as the inability of the uterine cervix to retain the growing conceptus, often presenting with spontaneous and painless cervical dilation, bulging of fetal membranes within the second trimester, leading to a spectrum of presentation: protrusion (hourglassing) of the fetal membranes into the upper vagina, membrane rupture, and/or spontaneous labour and delivery. This classic description presents the obstetrician with problems. Firstly, there is no reliable diagnostic preconceptual test to estimate whether a cervix is able to retain a pregnancy [46]. Secondly, the clinical presentations are not necessarily unique to cervical insufficiency [47,48]. A working definition of cervical insufficiency is therefore essentially *post-hoc*, ‘in which a cervical

cerclage (inserting a stitch) is likely to improve pregnancy outcome’ [48]. The diagnosis therefore needs to be used with caution, as cerclage may not be necessary (but may incur potentially hazardous surgery), or may not be the most appropriate intervention if another aetiology is present [32].

The diagnosis of cervical insufficiency is clinically determined upon the observation of progressive cervical shortening in pregnancy using transvaginal ultrasonography. There is evidence to suggest that a short cervix is related to preterm birth [49], and this relationship is further strengthened if there is a history of preterm birth [50,51] or if progressive shortening is noted during pregnancy. Nevertheless, cervical shortening may also occur as a result of premature tissue modelling due to other pathways leading to the generation of inflammatory mediators (such as placental bleeding), and therefore is not unique to mechanical insufficiency [2]. Furthermore, an obstetric history of cervical insufficiency is not a reliable predictor of cervical length in the next pregnancy [50]. In turn, transvaginal ultrasonography is used as a predictor of preterm birth based on cervical length over time, but alone it is not suitable to distinguish cervical insufficiency from other causes of preterm birth [48].

As mentioned, attempting to diagnose cervical insufficiency outside pregnancy is problematic. A diagnosis of insufficiency is suggested if a woman has a history of mid-trimester loss and the cervical canal is wider than 8 mm in diameter when measured directly or if it permits introduction of a similarly-sized probe with minimal resistance [52]. However, these diagnostic criteria do not take into account the effects of the menstrual cycle on the diameter of the cervical canal and internal cervical os (Fig. 1) [4,26,53]. Furthermore, cervical remodelling is a dynamic process that may involve complex biochemical and anatomical interplay, which these tests do not allow for [54,55].

## 7. Future research and the internal cervical os

Cervical insufficiency remains a condition that is poorly understood and as a consequence remains a diagnosis of exclusion. The estimated prevalence of the condition is likely to be much higher than its true incidence because an adequate definition does not exist within the literature. Furthermore, although potential risks that may increase the chances of cervical insufficiency have been identified, there is no complete pathway explaining why the cervix is sometimes too weak to retain the growing conceptus.

The consequence of this knowledge gap is that cervical cerclage is overly prescribed [56] despite a short cervix not necessarily consequent upon a structural weakness within the cervix or vice-versa [35]. The effectiveness of cervical cerclage remains unclear and the literature is unable to establish a clinical population in which cerclage may be of true benefit [32]. The original literature pertaining to cervical cerclage state that unless an anatomical lesion is identified, surgical repair of a weak cervix should not be carried out [57]. As the original purpose of cervical cerclage was to repair a weakened internal cervical os, it may be necessary to reconsider altered anatomy of the internal os as a cause of cervical insufficiency, and to possibly consider it as a separate pathology.

The ability of the cervix to retain and protect the fetus during pregnancy is clearly centred around the internal os. It is thought that an occlusive muscular structure is likely to be present at the level of the internal os [58], yet this has not been identified histologically [14,19]. However, histomorphometric measurements have shown that the proportion of smooth muscle within the cervical stroma progressively increases towards the internal os, with smooth muscle being most abundant at this level [59,60].

Observations within a clinical setting suggest that an occlusive mechanism does exist at the level of the upper aspect of the cervical

canal. It is recognized that when a dilator is inserted into the cervical canal, resistance is encountered approximately 2–3 cm past the external cervical os. During hystero-graphy, the opaque medium used also encounters slight resistance before passing into the uterus. Furthermore, as previously mentioned (section 3.1), radiographic studies have also provided evidence of an area within the proximal portion of the cervical canal that shows cyclical changes in its diameter [4,26].

MRI and ultrasound studies suggest that the anatomical structure that is essential to cervical function is proximal portion also known anatomically as the internal os [1]. Sonographic studies show that cervical effacement begins here and proceeds distally [61], and in cases of premature cervical effacement, a weakened internal os may be responsible for the protrusion of fetal membranes into the cervical canal (funneling) within the second trimester.

Further research needs to consider the anatomy of the internal os and its occlusive nature. In previous histologic research of the cervix two-dimensional methods of analysis were used. Smooth muscle was identified in being most abundant at the level of the internal os [62], yet it was concluded that these muscular bundles were not functional. Future research could employ methods to analyse this anatomical region in three dimensions, using small bore MRI, and in 3D reconstructive modelling using digitised histologic sections [63]. In doing so, such methods would be able to confirm whether the muscular bundles at the internal os are organised in such a way as to explain the sphincteric behaviour that has been observed in this region, and show the way forward in developing clinical tools to accurately diagnose and treat this condition prior to pregnancy.

## 8. Conclusion

The cervix is critical to conception and the maintenance of pregnancy, particularly during the second trimester. Structural abnormalities of the cervix leading to preterm birth are not fully understood. The internal cervical os is central to preserving an effective barrier to ascending microorganisms; weakness may increase the risk their triggering preterm birth. Reconstructive research techniques may further determine the anatomy of the cervix in the region of the internal os, defining its role in normal pregnancies and those complicated by prematurity.

## Acknowledgements

This work was supported by Cerebra UK.

## References

- [1] K.M. Myers, H. Felto-vich, E. Mazza, J. Vink, M. Bajka, R.J. Wapner, et al., The mechanical role of the cervix in pregnancy, *J. Biomech.* 48 (2015) 1511–1523, <http://dx.doi.org/10.1016/j.jbiomech.2015.02.065>.
- [2] M.G. Gravett, C.E. Rubens, T.M. Nunes, Global report on preterm birth and stillbirth (2 of 7): discovery science, *BMC Pregnancy Childbirth* (10 suppl. 1) (2010) S2, <http://dx.doi.org/10.1186/1471-2393-10-S1-S2>.
- [3] G.S. Anthony, J. Fisher, J.R. Coutts, A.A. Calder, Forces required for surgical dilatation of the pregnant and non-pregnant human cervix, *Br. J. Obstet. Gynaecol.* 89 (1982) 913–916. <http://www.ncbi.nlm.nih.gov/pubmed/7171498> (accessed 25.08.15).
- [4] J. Asplund, The uterine cervix and isthmus under normal and pathological conditions; a clinical and roentgenological study, *Acta Radiol. Suppl.* 91 (1952) 1–76. <http://www.ncbi.nlm.nih.gov/pubmed/14933234> (accessed 05.12.14).
- [5] A. Singer, J. Jordan, The functional anatomy of the cervix, the cervical epithelium and the stroma, in: J. Jordan, A. Singer, H. Jones III, M. Shafi (Eds.), *The Cervix, second ed.*, Blackwell, Malden, Massachusetts, 2006, pp. 13–37.
- [6] D. Vu, B.T. Haylen, K. Tse, A. Farnsworth, Surgical anatomy of the uterosacral ligament, *Int. Urogynecol. J.* 21 (2010) 1123–1128, <http://dx.doi.org/10.1007/s00192-010-1147-8>.
- [7] R. Ramanah, M.B. Berger, B.M. Parratte, J.O.L. DeLancey, Anatomy and histology of apical support: a literature review concerning cardinal and uterosacral ligaments, *Int. Urogynecol. J.* 23 (2012) 1483–1494, <http://dx.doi.org/10.1007/s00192-012-1819-7>.
- [8] J.M. Palacios Jaraquemada, R. García Mónaco, N.E. Barbosa, L. Ferle, H. Iriarte, H.A. Conesa, Lower uterine blood supply: extrauterine anastomotic system and its application in surgical devascularization techniques, *Acta Obstet. Gynecol. Scand.* 86 (2007) 228–234, <http://dx.doi.org/10.1080/00016340601089875>.
- [9] J.A. Walocha, J.A. Litwin, T. Bereza, W. Klimek-Piotrowska, A.J. Miodoński, Vascular architecture of human uterine cervix visualized by corrosion casting and scanning electron microscopy, *Hum. Reprod.* 27 (2012) 727–732, <http://dx.doi.org/10.1093/humrep/der458>.
- [10] T. Bereza, K.A. Tomaszewski, M. Balajewicz-Nowak, E. Mizia, A. Pasternak, J. Walocha, The vascular architecture of the supravaginal and vaginal parts of the human uterine cervix: a study using corrosion casting and scanning electron microscopy, *J. Anat.* 221 (2012) 352–357, <http://dx.doi.org/10.1111/j.1469-7580.2012.01550.x>.
- [11] C.R.B. Beckmann, F.W. Ling, B.M. Barzansky, W.N. Herbert, D.W. Laube, R.P. Smith, *Obstetrics and Gynecology*, sixth ed., Lippincott Williams & Wilkins, Baltimore, 2010. <https://books.google.com/books?id=0f1Wgd30JLEc&pgis=1> (accessed 05.08.15).
- [12] C.F. Fluhmann, The nature and development of the so-called glands of the cervix uteri, *Am. J. Obstet. Gynecol.* 74 (1957) 753–766 discussion 766–8, <http://www.ncbi.nlm.nih.gov/pubmed/13458281> (accessed 14.04.15).
- [13] T. Callahan, A.B. Caughey, *Blueprints Obstetrics and Gynecology*, sixth ed., Lippincott Williams & Wilkins, Baltimore, 2013. <https://books.google.com/books?id=eKC1B3BhlxUC&pgis=1> (accessed 05.08.15).
- [14] D.N. Danforth, The fibrous nature of the human cervix, and its relation to the isthmus segment in gravid and nongravid uteri, *Am. J. Obstet. Gynecol.* 53 (1947) 541–560.
- [15] D. Danforth, The distribution and functional activity of the cervical musculature, *Am. J. Obstet. Gynecol.* 68 (1954) 1261–1271. <http://europepmc.org/abstract/MED/13207218> (accessed 11.12.14).
- [16] Y. Gan, W. Yao, K.M. Myers, J.Y. Vink, R.J. Wapner, C.P. Hendon, Analyzing three-dimensional ultrastructure of human cervical tissue using optical coherence tomography, *Biomed. Opt. Express* 6 (2015) 1090–1108, <http://dx.doi.org/10.1364/BOE.6.001090>.
- [17] K.M. Myers, C.P. Hendon, Y. Gan, W. Yao, K. Yoshida, M. Fernandez, et al., A continuous fiber distribution material model for human cervical tissue, *J. Biomech.* 48 (2015) 1533–1540, <http://dx.doi.org/10.1016/j.jbiomech.2015.02.060>.
- [18] R.M. Aspden, Collagen organisation in the cervix and its relation to mechanical function, *Coll. Relat. Res.* 8 (1988) 103–112, [http://dx.doi.org/10.1016/S0174-173X\(88\)80022-0](http://dx.doi.org/10.1016/S0174-173X(88)80022-0).
- [19] P.E. Hughesdon, The fibromuscular structure of the cervix and its changes during pregnancy and labour, *BJOG Int. J. Obstet. Gynaecol.* 59 (1952) 763–776, <http://dx.doi.org/10.1111/j.1471-0528.1952.tb14758.x>.
- [20] D.N. Danforth, The morphology of the human cervix, *Clin. Obstet. Gynecol.* 26 (1983) 7–13. [http://journals.lww.com/clinicalobgyn/Abstract/1983/03000/The\\_Morphology\\_of\\_the\\_Human\\_Cervix.5.aspx](http://journals.lww.com/clinicalobgyn/Abstract/1983/03000/The_Morphology_of_the_Human_Cervix.5.aspx) (accessed 11.12.14).
- [21] P. Leppert, S. Keller, Conclusive evidence for the presence of elastin in human and monkey cervix, *Am. J. Obstet. Gynecol.* 142 (1982) 179–182. <http://www.ncbi.nlm.nih.gov/pubmed/7055182> (accessed 11.12.14).
- [22] P.C. Leppert, S. Keller, J. Cerreta, Y. Hosannah, I. Mandl, The content of elastin in the uterine cervix, *Arch. Biochem. Biophys.* 222 (1983) 53–58, [http://dx.doi.org/10.1016/0003-9861\(83\)90501-5](http://dx.doi.org/10.1016/0003-9861(83)90501-5).
- [23] P. Leppert, J. Cerreta, I. Mandl, Orientation of elastic fibers in the human cervix, *Am. J. Obstet. Gynecol.* 155 (1986) 219–224, <http://www.sciencedirect.com/science/article/pii/0002937886901158> (accessed 11.12.14).
- [24] D. Rotten, C. Gavignet, M.C. Colin, A.M. Robert, G. Godeau, Evolution of the elastic fiber network of the human uterine cervix before, during and after pregnancy. A quantitative evaluation by automated image analysis, *Clin. Physiol. Biochem.* 6 (1988) 285–292. <http://www.ncbi.nlm.nih.gov/pubmed/3229071> (accessed 05.12.14).
- [25] S. McCarthy, C. Tauber, J. Gore, Female pelvic anatomy: MR assessment of variations during the menstrual cycle and with use of oral contraceptives, *Radiology* 160 (1986) 119–123, <http://dx.doi.org/10.1148/radiology.160.1.3715022>.
- [26] A.F. Youssef, The uterine isthmus and its sphincter mechanism, a radiographic study: the uterine isthmus under normal conditions, *Am. J. Obstet. Gynecol.* 75 (1958) 1305–1319.
- [27] K. Sharif, O. Olufowobi, The structure, chemistry and physics of human cervical mucus, in: J. Jordan, A. Singer (Eds.), *The Cervix, second ed.*, Blackwell, 2006, pp. 157–168.
- [28] F. Martyn, F.M. McAuliffe, M. Wingfield, The role of the cervix in fertility: is it time for a reappraisal? *Hum. Reprod.* 29 (2014) 2092–2098, <http://dx.doi.org/10.1093/humrep/deu195>.
- [29] N. Becher, K. Adams Waldorf, M. Hein, N. Uldbjerg, The cervical mucus plug: structured review of the literature, *Acta Obstet. Gynecol. Scand.* 88 (2009) 502–513, <http://dx.doi.org/10.1080/00016340902852898>.
- [30] V.C. Heath, T.R. Southall, A.P. Souka, A. Elisseou, K.H. Nicolaidis, Cervical length at 23 weeks of gestation: prediction of spontaneous preterm delivery, *Ultrasound Obstet. Gynecol.* 12 (1998) 312–317, <http://dx.doi.org/10.1046/j.1469-0705.1998.12050312.x>.
- [31] H. Gee, *Mechanics, biochemistry and pharmacology of the cervix and labour*, in: J. Singer, H. Jones III, M. Shafi (Eds.), *The Cervix, second ed.*, Blackwell,

- Malden, Massachusetts, 2006, pp. 183–193.
- [32] Royal College of Obstetricians and Gynaecologists, Green-top Guideline No. 60: Cervical Cerclage, 2011.
- [33] R. Parikh, A. Patel, T. Stack, S. Socrate, M. House, How the cervix shortens: an anatomic study using 3-dimensional transperineal sonography and image registration in singletons and twins, *J. Ultrasound Med.* 30 (2011) 1197–1204. <http://www.ncbi.nlm.nih.gov/pubmed/21876090> (accessed 14.04.15).
- [34] M. Goya, L. Pratcorona, C. Merced, C. Rodó, L. Valle, A. Romero, et al., Cervical pessary in pregnant women with a short cervix (PECEP): an open-label randomised controlled trial, *Lancet (Lond. Engl.)* 379 (2012) 1800–1806. [http://dx.doi.org/10.1016/S0140-6736\(12\)60030-0](http://dx.doi.org/10.1016/S0140-6736(12)60030-0).
- [35] M. House, R. McCabe, S. Socrate, Using imaging-based, three-dimensional models of the cervix and uterus for studies of cervical changes during pregnancy, *Clin. Anat.* 26 (2013) 97–104. <http://dx.doi.org/10.1002/ca.22183>.
- [36] M. House, M. O'Callaghan, S. Bahrami, D. Chelmos, J. Kini, D. Wu, et al., Magnetic resonance imaging of the cervix during pregnancy: effect of gestational age and prior vaginal birth, *Am. J. Obstet. Gynecol.* 193 (2005) 1554–1560. <http://dx.doi.org/10.1016/j.ajog.2005.03.042>.
- [37] M. House, R.A. Bhadelia, K. Myers, S. Socrate, Magnetic resonance imaging of three-dimensional cervical anatomy in the second and third trimester, *Eur. J. Obstet. Gynecol. Reprod. Biol.* 144 (Suppl) (2009) S65–S69. <http://dx.doi.org/10.1016/j.ejogrb.2009.02.027>.
- [38] M. Parikh, M. Rasmussen, L. Brubaker, C. Salomon, K. Sakamoto, R. Evenhouse, et al., Three dimensional virtual reality model of the normal female pelvic floor, *Ann. Biomed. Eng.* 32 (2004) 292–296. <http://dx.doi.org/10.1023/B:ABME.0000012749.79488.d6>.
- [39] C.T. Lang, J.D. Iams, E. Tangchitnob, S. Socrate, M. House, A method to visualize 3-dimensional anatomic changes in the cervix during pregnancy: a preliminary observational study, *J. Ultrasound Med.* 29 (2010) 255–260. <http://www.ncbi.nlm.nih.gov/pubmed/20103797> (accessed 15.04.15).
- [40] B. Timmons, M. Akins, M. Mahendroo, Cervical remodeling during pregnancy and parturition, *Trends Endocrinol. Metab.* 21 (2010) 353–361. <http://dx.doi.org/10.1016/j.tem.2010.01.011>.
- [41] L. Peralta, G. Rus, N. Bochud, F.S. Molina, Mechanical assessment of cervical remodeling in pregnancy: insight from a synthetic model, *J. Biomech.* 48 (2015) 1557–1565. <http://dx.doi.org/10.1016/j.jbiomech.2015.02.037>.
- [42] March of Dimes, PMNCH, Save the Children, WHO, WHO/Born Too Soon: the Global Action Report on Preterm Birth, World Health Organization, Geneva, 2012. [http://www.who.int/pmnch/media/news/2012/preterm\\_birth\\_report/en/index1.html](http://www.who.int/pmnch/media/news/2012/preterm_birth_report/en/index1.html) (accessed 02.03.15).
- [43] C.R.B. Beckmann, W. Herbert, D. Laube, F. Ling, R. Smith, *Obstetrics and Gynecology*, Lippincott Williams & Wilkins, 2013. <http://books.google.com/books?id=dD-emqhOXa0C&pgis=1> (accessed 05.12.14).
- [44] H.H. Chang, J. Larson, H. Blencowe, C.Y. Spong, C.P. Howson, S. Cairns-Smith, et al., Preventing preterm births: analysis of trends and potential reductions with interventions in 39 countries with very high human development index, *Lancet* 381 (2013) 223–234. [http://dx.doi.org/10.1016/S0140-6736\(12\)61856-X](http://dx.doi.org/10.1016/S0140-6736(12)61856-X).
- [45] C. Ortinau, J. Neil, The neuroanatomy of prematurity: normal brain development and the impact of preterm birth, *Clin. Anat.* 28 (2015) 168–183. <http://dx.doi.org/10.1002/ca.22430>.
- [46] S.S. Hassan, R. Romero, F. Gotsch, R.N. Nikita, T. Chaiworapongsa, Cervical insufficiency, in: H. Winn, F. Chervenak, R. Romero (Eds.), *Clin. Matern. Med. Online*, Informa Healthcare, 2011.
- [47] R. Farquharson, The incompetent cervix, in: J. Jordan, A. Singer (Eds.), *The Cervix*, second ed., Blackwell, Malden, Massachusetts, 2006, pp. 194–205.
- [48] J.D. Iams, Cervical insufficiency, in: R.K. Creasy, R. Resnick, J.D. Iams, C.J. Lockwood, T.R. Moore (Eds.), *Creasy Resnic. Matern. Med. Princ. Pract.*, sixth ed., 2009. Philadelphia, PA.
- [49] J.D. Iams, R.L. Goldenberg, P.J. Meis, B.M. Mercer, A. Moawad, A. Das, et al., The length of the cervix and the risk of spontaneous premature delivery. National Institute of Child Health and Human Development Maternal Fetal Medicine Unit Network, *N. Engl. J. Med.* 334 (1996) 567–572. <http://dx.doi.org/10.1056/NEJM199602293340904>.
- [50] J.D. Iams, F.F. Johnson, J. Sonek, L. Sachs, C. Gebauer, P. Samuels, Cervical competence as a continuum: a study of ultrasonographic cervical length and obstetric performance, *Am. J. Obstet. Gynecol.* 172 (1995) 1097–1103 discussion 1104–6. <http://www.ncbi.nlm.nih.gov/pubmed/7726247> (accessed 05.12.14).
- [51] E.R. Guzman, R. Mellon, A.M. Vintzileos, C.V. Ananth, C. Walters, K. Gipson, Relationship between endocervical canal length between 15–24 weeks gestation and obstetric history, *J. Matern. Fetal. Med.* 7 (1998) 269–272. [http://dx.doi.org/10.1002/\(SICI\)1520-6661\(199811/12\)7:6<269::AID-MFM3>3.0.CO;2-4](http://dx.doi.org/10.1002/(SICI)1520-6661(199811/12)7:6<269::AID-MFM3>3.0.CO;2-4).
- [52] G.S. Anthony, R.G. Walker, J.B. Robins, A.D. Cameron, A.A. Calder, Management of cervical weakness based on the measurement of cervical resistance index, *Eur. J. Obstet. Gynecol. Reprod. Biol.* 134 (2006) 174–178. <http://dx.doi.org/10.1016/j.ejogrb.2006.10.006>.
- [53] J.H. Harger, Cerclage and cervical insufficiency: an evidence-based analysis, *Obstet. Gynecol.* 100 (2002) 1313–1327. <http://www.ncbi.nlm.nih.gov/pubmed/12468179> (accessed 05.12.14).
- [54] R.A. Word, X.-H. Li, M. Hnat, K. Carrick, Dynamics of cervical remodeling during pregnancy and parturition: mechanisms and current concepts, *Semin. Reprod. Med.* 25 (2007) 69–79. <http://dx.doi.org/10.1055/s-2006-956777>.
- [55] V.M. Parisi, Cervical incompetence and preterm labor, *Clin. Obstet. Gynecol.* 31 (1988) 585–598. <http://www.ncbi.nlm.nih.gov/pubmed/3224459> (accessed 11.12.14).
- [56] O.A. Rust, R.O. Atlas, K.J. Jones, B.N. Benham, J. Balducci, A randomized trial of cerclage versus no cerclage among patients with ultrasonographically detected second-trimester preterm dilatation of the internal os, *Am. J. Obstet. Gynecol.* 183 (2000) 830–835. <http://dx.doi.org/10.1067/mob.2000.109040>.
- [57] F. Rubovits, N. Cooperman, A. Lash, Habitual abortion: a radiographic technique to demonstrate the incompetent internal os of the cervix, *Am. J. Obstet. Gynecol.* 66 (1953) 269–280. <http://europepmc.org/abstract/MED/13065331> (accessed 11.12.14).
- [58] T.B. FitzGerald, The obstetric capacity of the undilated cervix, *BJOG Int. J. Obstet. Gynaecol.* 56 (1949) 229–236. <http://dx.doi.org/10.1111/j.1471-0528.1949.tb07091.x>.
- [59] B.S. Oxlund, G. Ørtoft, A. Brüel, C.C. Danielsen, H. Oxlund, N. Ulbjerg, Cervical collagen and biomechanical strength in non-pregnant women with a history of cervical insufficiency, *Reprod. Biol. Endocrinol.* 8 (2010) 92. <http://dx.doi.org/10.1186/1477-7827-8-92>.
- [60] D. Rorie, M. Newton, Histologic and chemical studies of the smooth muscle in the human cervix and uterus, *Am. J. Obstet. Gynecol.* 99 (1967) 466–469. <http://www.ncbi.nlm.nih.gov/pubmed/4167498> (accessed 11.12.14).
- [61] M. Williams, J.D. Iams, Cervical length measurement and cervical cerclage to prevent preterm birth, *Clin. Obstet. Gynecol.* 47 (2004) 775–783.
- [62] D.K. Rorie, M. Newton, Histologic and chemical studies of the smooth muscle in the human cervix and uterus, *Am. J. Obstet. Gynecol.* 99 (1967) 466–469. <http://www.ncbi.nlm.nih.gov/pubmed/4167498> (accessed 05.12.14).
- [63] N. Roberts, D. Magee, Y. Song, K. Brabazon, M. Shires, D. Crellin, et al., Toward routine use of 3D histopathology as a research tool, *Am. J. Pathol.* 180 (2012) 1835–1842. <http://dx.doi.org/10.1016/j.ajpath.2012.01.033>.