UNIVERSITY OF LEEDS

This is a repository copy of *The impact of digital image processing artefacts mimicking pathological features associated with restorations*.

White Rose Research Online URL for this paper:
http://eprints.whiterose.ac.uk/74427/

Article:
Brettle, D and Carmichael, F (2011) The impact of digital image processing artefacts mimicking pathological features associated with restorations. British Dental Journal, 211 (4). 167 - 170 . ISSN 0007-0610

https://doi.org/10.1038/sj.bdj.2011.676

Reuse
See Attached

Takedown
If you consider content in White Rose Research Online to be in breach of UK law, please notify us by emailing eprints@whiterose.ac.uk including the URL of the record and the reason for the withdrawal request.

White Rose university consortium
Universities of Leeds, Sheffield & York

eprints@whiterose.ac.uk
https://eprints.whiterose.ac.uk/

D. Brettle & F. Carmichael.The impact of digital image processing artefacts mimicking pathological features associated with restorations. (2011). British Dental Journal. 211:167 – 170.

Published: 26 August 2011| doi:10.1038/sj.bdj.2011.676

http://www.nature.com/bdj/journal/v211/n4/abs/sj.bdj.2011.676.html

Pre publication version: The impact of digital image processing artefacts mimicking pathological features associated with restorations.

David Brettle PhD, MSc, BSc, FIPEM[1] and

Fiona Carmichael BDS, FDS, DDR, MSc[2].

1) Medical Physics and Engineering, The Old Medical School, Leeds General Infirmary, Leeds, LS1 3EX.

2) Dental Radiology, Leeds Dental Institute, The Worseley Building, Clarendon Way, Leeds, LS2 9LU

Abstract

Background Image processing of digital x-ray images is known to have the potential to produce artefacts that may mimic pathology. A study was conducted at a UK dental radiology conference to demonstrate this effect in dentistry.

Method Sixteen digital x-rays of single teeth containing restorations were randomly presented in both unprocessed and processed formats to an auditorium of 42 participants. Participants interactively scored each image on a scale from 1 – 5 where 1 was definitely no pathology and 5 was definitely pathology. The display conditions were confirmed for each participant using a validated threshold contrast test.

Results The results show that 52% (81/157) of responses at level 1 for the unprocessed images changed to levels 4 or 5 after image processing.

Conclusion This study demonstrates the potential for image processing artefacts to mimic pathology particularly at high contrast boundaries and introduces the risk of unnecessary interventions. In order to minimise this risk, it is recommended that for digital radiographs, containing pathology relating to high contrast boundaries, non-related high contrast features such as unrelated restorations or tooth/bone margins are also considered to exclude the possibility of artefact. If there is doubt, reference should be made to the unprocessed data.

Introduction

Digital imaging is increasingly becoming 'de rigueur' for x-ray imaging in the 21st century. The advantages of the rapid acquisition, delivery and display of image data outweigh any potential compromises in image quality[1, 2]. All digital data is processed at several different levels prior to display. Image processing may be local to a specific area in the image for example to remove dead pixels or global across the whole image to improve visualisation by enhancing or suppressing certain elements in the image. Many of these processes are outside of the user control although most systems provide post processing options. The Unsharp Mask Subtraction (UMS) algorithm has been widely adopted as the most common process for general image processing as it enhances both contrast and sharpness. It is also efficient with respect to speed and does not require high-end computational power. Many systems still use this algorithm in varying degrees of sophistication but as computer power has increased, so too has the complexity of the algorithms. Recent methods favour multi scalar processing which operates on multiple derivatives of the original data, each at different spatial scales [3].

Image processing is intended to improve the image presentation but it is also possible, especially for non-adaptive algorithms, to produce an artefact that has a deleterious impact on the image by mimicking the presence of pathology. A classic example of this is the 'halo' artefact produced by the UMS, also referred to as the 'Ubberschwinger' or 'rebound' artefact[4, 5]. In its simplest form the UMS process requires the subtraction of a blurred version of the original image, from the original. The amount of blur gives the algorithm frequency selective capabilities. The halo

occurs because the blurred image contains edges that are wider than in the original so that on subtraction a residual inverted contrast boundary is produced. Where high intensity boundaries occur in the images, e.g. around bone or metal the impact of any blur is greater, resulting in a more pronounced shadow effect. (see figure 1).

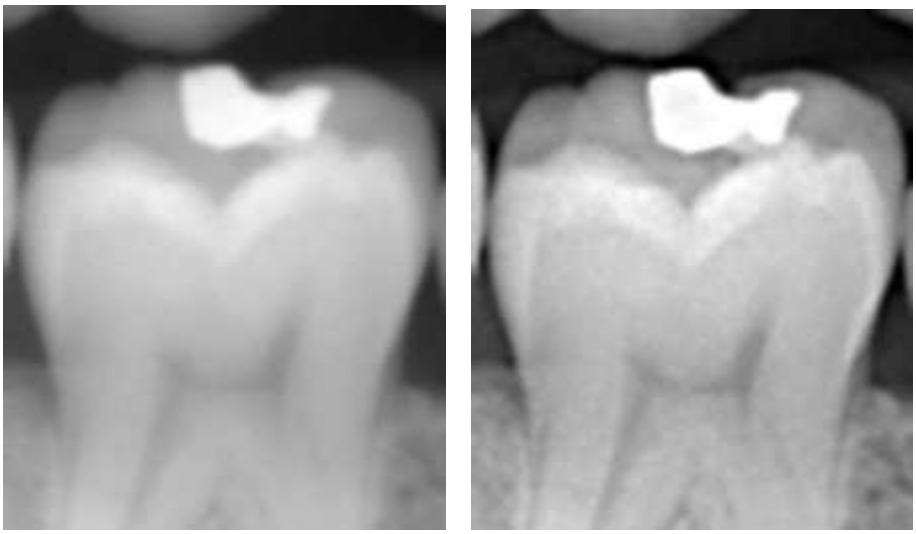

a) b)

Figure 1: Example of the unsharp mask subtraction process introducing the halo artefact around the lower edge of the restoration and the tooth margin. a) Unprocessed Image. b) Processed with the Unsharp Mask (Blur radius =18 pixels).

This can mimic boundary changes relating to genuine pathology and in general radiology includes prosthetic loosening, pneumothorax, pneumomediastinum and diaphragmatic calcification [4-6]. A recent case example highlighted the potential for the halo artefact emanating from restoration boundaries to be misdiagnosed as misfit of the luted definitive restoration or caries[7]. Although the UMS artefact is quite gross it clearly demonstrates the potential for artefacts to mimic genuine

pathology. Even relatively benign processing such as edge enhancement, if excessively applied, can mimic pathology such as osteolytic lesions and Pagets disease [8]

Image processing artefact is still present in the more sophisticated algorithms but is often more subtle or reduced which makes it harder for the observer to identify the presence of any unintended artefacts.

A previous publication has proposed methods for introducing a digital frame of reference into an image that readily allows the nature of an artefact to be isolated and provide feedback to the user on whether a perceived pathology may in fact be artefactual[9]. This method is not currently suitable for dental radiology because of its physical size.

Radiology in general dental practice is one area where the adoption of digital imaging has lagged behind general radiology due to the costs and the large number of practices involved. However the affordability and image quality of new digital systems are improving and there is an increasing momentum towards digital. But with the prevalence of restorations, the large number of disparate systems and the large user base there is an increased opportunity for induced artefacts to be misdiagnosed as genuine pathology potentially altering treatment decisions.

At a national conference on dental and maxillofacial radiology (BSDMFR 50th meeting, London, September 2008) an interactive demonstration of the potential to

mimic recurrent caries or failing crown margins was conducted.

The results of this study are presented in this paper to highlight the potential risks in using image processing. This is particularly relevant in dental radiology where there is a prevalence of high contrast boundaries relating to pathological changes.

Method

16 image segments were taken from digital panoramic images acquired on a Fuji Capsula XC Computed Radiography system (Bedford, UK). Each segment was chosen to have only 1 focus tooth and were selected by a consultant radiologist to cover a range of presentations of recurrent caries or crown margin failures. All images were exported with no image processing applied. The images were then processed using an unsharp mask algorithm in ImageJ (NIH, http://rsbweb.nih.gov/ij/) with a filter size of 15 and a weighting of 0.6. These parameters were chosen by the experiment controller such that the end presentation was representative of clinical processing. The total image set of 16 raw and 16 processed images were randomly interleaved in presentation order and one image in each pair was randomly selected and flipped about the horizontal axis to help prevent recognition when viewed.

The images were imported into a PowerPoint (Microsoft, Reading, UK) presentation which had been integrated with the Turning Point (Reivo Ltd, Berkshire, UK) interactive audience feedback system. This system collects participant responses to the slide displayed using a numeric keypad. Prior to the study an information sheet was distributed amongst the audience explaining the nature of the experiment and

setting out methods for consenting and withdrawing from the study. The presentation was shown to the audience at a dental radiology conference under lighting conditions that had been established as allowing the users to see the keypad with the minimum ambient light. The first few slides in the presentation reiterated the nature of the experiment and the ability to withdraw at any time. The pathology to look for was also stated as:

> "Where there is a coronal restoration (this can be mesial/distal and/or occlusal) is there recurrent caries?
>
> Where there is a crown, is there a failing crown margin?"

and a visual example of the extremes of range of presentations was also shown (see figure 2).

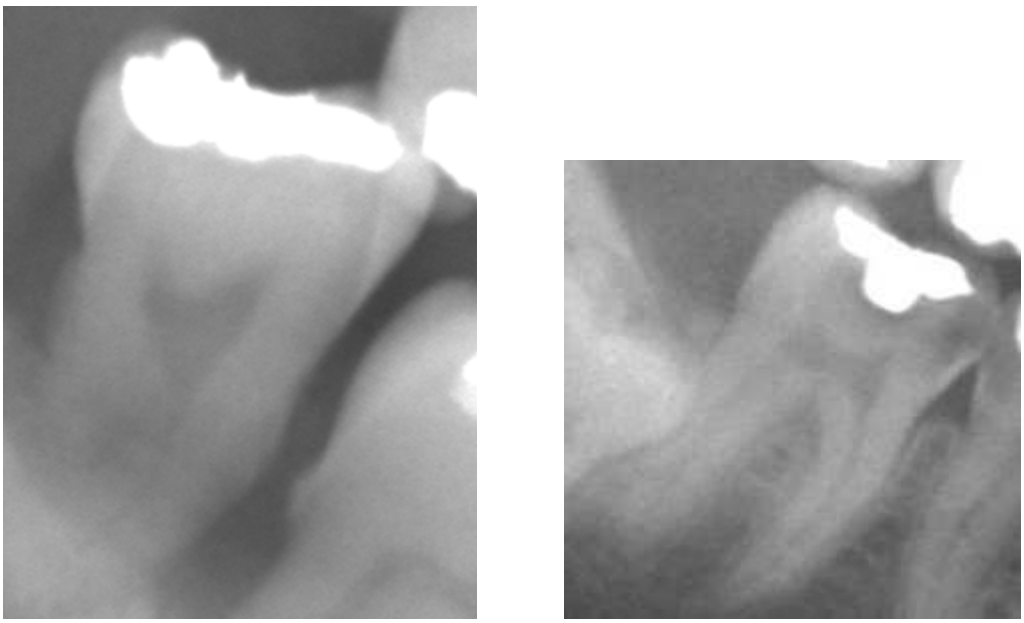

a) b)

Figure 2: Visual examples of the extremes of the scoring scheme. a) designated a score of 1. b) designated a score of 5.

The first interactive slide in the presentation asked the user to confirm whether they consented or not to take part, the second collected the occupation of the participant and was the only demographic data collected. All the responses were correlated against keypad but this was not related to individual users. The subsequent 4 slides were based on the verified login system[10] and presented numbers on backgrounds at 0%, 50% and 100% grey level range. All the numbers were 5% above the background and the user had to repeat the number on their keypad. In this way the minimal level of contrast resolution for each participant was validated. The following slide sequence showed the raw and processed images in their random sequence. The participant indicated their confidence of pathology for each image as:

1=Definitely no pathology,

2=Probably no pathology

3=Possibly pathology

4=Probably pathology

5=Definitely pathology.

These options were shown on each image slide as an aide memoir.

The data was exported into Excel (Microsoft, Reading, UK) for analysis.

Results

Of the 53 members of the audience who responded 49 consented to take part in this study. Of these 7 were withdrawn from the study by the experiment controller; 2 because they had failed the verified login and 5 as they had 3 or more null results in a row and were deemed to have withdrawn from the study as per the study

information sheet.

The demographics for the validated participants are shown in table 1.

Group	**Number**
Consultant radiologists	17
SpR Radiologists	1
Radiographers	10
Other clinical	8
Other	6

Table 1: Demographics for the validated participants.

Figure 3 shows an image pair used in the study processed. The scores in these images changed from an average of 1.62 for the unprocessed image to 3.97 in the processed image for all observers.

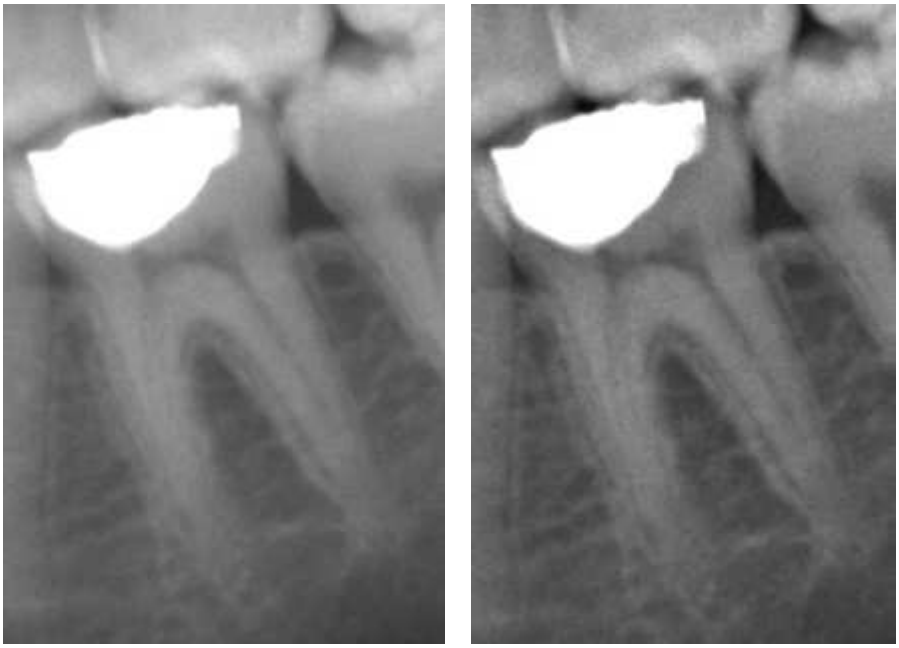

a) b)

Figure 3. Example of one image pair used in the study a) Unprocessed Image b) Processed with the Unsharp Mask. The scores in these images changed from an average of 1.62 to 3.97.

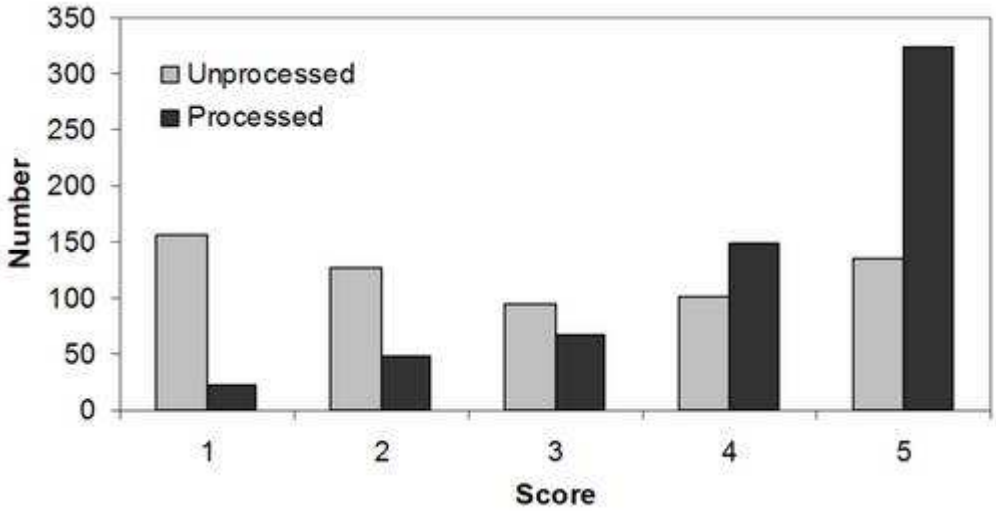

Figure 4: Results for all participants and all images for pre and post processing. (n=617).

Figure 4 shows all the responses for the unprocessed and processed images. It can be seen that there is a reasonably even spread of occurrences at each confidence level for the unprocessed data but this is skewed to the high scores after processing. Figure 5 shows how the level 1 response on the unprocessed images changed after processing.

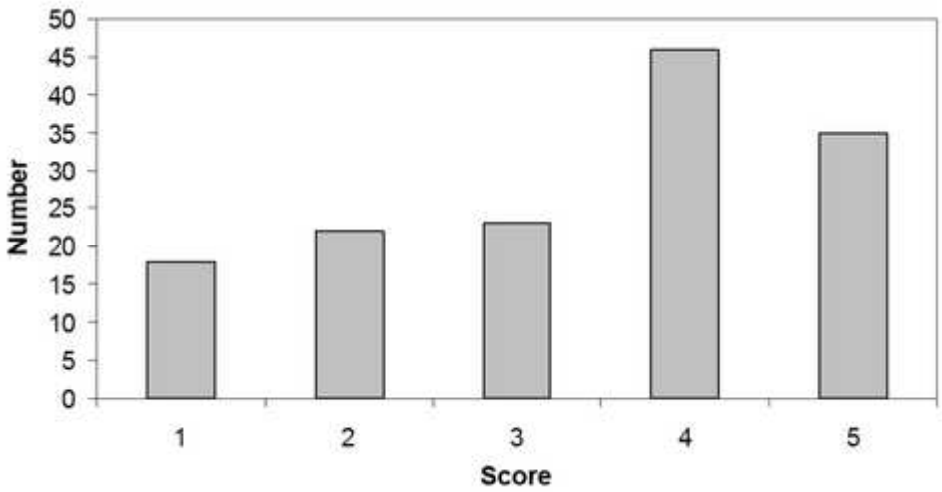

Figure 5: Showing how a 1 score on the unprocessed image changed after processing. (n=157). Only 11% (18/157) remained unchanged after processing.

Discussion

In psychophysical studies large numbers of observers are required, however for certain groups, for example consultant radiologists, achieving these high numbers is difficult. This study utilised a novel method for a large scale observer trial. The key elements that facilitated this were a large cohort of relevant health professionals attending a conference, interactive key pads to record responses to test images and the use of the verified login method to validate the minimum contrast sensitivity of each observer in the auditorium. The experimental management was also expedited by the use of the key pads allowing demographic, and consent information to be rapidly collected. In total the experiment lasted for 20 minutes. Training, both in the use of the key pads and the diagnostic task were addressed by a warm up session at the beginning of the experiment and the collection of the support information. Two participants failed the verified login test. This could have been due to keypad error, misunderstanding of the test or contrast acuity issues but it was not possible in this study to identify the exact cause. It is important to note that this type of test is not designed to test spatial resolution just contrast. In the task proposed spatial resolution was of lesser concern than contrast.

This is thought to be the first time this method of validated participation in large scale observer studies has been employed and adds a new option for studies of this type.

Although the possibility of image artefacts mimicking pathology is well known, especially for the common algorithms, the clinical impact is not well demonstrated. In dental radiographs the halo effect is particularly evident due to the prevalence of high contrast signal boundaries.

Although, anecdotally, frequent users of digital systems do recognise the halo effect and adapt their interpretation accordingly a misdiagnosis may still arise with new users, locums or remote reporting. Additionally more complex adaptive algorithms may produce artefacts that are less obvious and therefore harder to recognise.

In this study the intent was to illustrate the potential for the halo effect to be misinterpreted as genuine pathology in the presence of restorations and was conducted as an educational demonstration. However the novel, and robust, experimental design coupled with the significant results has prompted wider dissemination especially considering the paucity of clinical results in this area.

In the analysis of the study results scores of 1 or 2 were deemed to require no intervention. A score of 3 would require watching and scores of 4 or 5 could solicit intervention. Therefore a significant change was considered to be a score of 1 or 2 changing to a 4 or 5 i.e. a change from ‘do nothing’ to ’intervene’. It is emphasised that the x-ray is only one diagnostic tool and clinical presentation / examination has not been considered in this study and may have moderated any intervention.

In order to minimise the potential to misdiagnose artefact as genuine pathology, it is recommended that for all digital radiographs containing pathology relating to high contrast boundaries, non-related high contrast features, such as unrelated restorations

or tooth/bone margins, are also considered to confirm the presence of artefact. If there is still doubt the raw data should be referred to.

Conclusion

We believe that the experimental methodology presented opens up the opportunity for fast and robust large scale observer studies. The study results demonstrate the potential for image processing artefacts to mimic pathology that cannot be discriminated from genuine pathology. Users of digital systems should be aware of this and if in doubt reference non-related high contrast signals to confirm the presence of artefact and ultimately refer to the raw data.

Acknowledgements

The authors would like to thank the British Society of Dental and Maxillofacial Radiology for supporting this study.

References

1. Brennan J. An introduction to digital radiography in dentistry. J Orthod. 2002 March 1, 2002;29(1):66-9.

2. Christensen GJ. Why switch to digital radiography? J Am Dent Assoc. 2004 October 1, 2004;135(10):1437-9.

3. Vuylsteke P, Schoeters E. Image Processing in Computed Radiography. Proceedings of the International Symposium on Computerized Tomography for Industrial Applications and Image Processing in Radiology. 1999:87-101.

4. Tan TH, Boothroyd AE. Uberschwinger artefact in computed radiographs. Br J Radiol. 1997;70(832):431.

5. Oestmann JW, Prokop M, Schaefer CM, Galanski M. Hardware and software artifacts in storage phosphor radiography. Radiographics. 1991;11(5):795-805.

6. Solomon SL, Jost RG, Glazer HS, Sagel SS, Anderson DJ, Molina PL. Artifacts in computed radiography. Am J Roentgenol. 1991;157(1):181-5.

7. Schweitzer DM, Berg RW. A digital radiographic artifact: A clinical report. The Journal of Prosthetic Dentistry. 2010;103(6):326-9.

8. Tan LTH, Ong KL. Artifacts in computed radiography. Hong Kong Journal of Emergency Medicine. 2000;7:27-32.

9. Brettle DS. A digital frame of reference for viewing digital images. British Journal of Radiology. 2001;74(877):69-72.

10. Brettle DS, Bacon SE. A method for verified access when using soft copy display. British Journal of Radiology. 2005;78(932):749-51.