



UNIVERSITY OF LEEDS

This is a repository copy of *Ultrasound by emergency physicians to detect abdominal aortic aneurysms: a UK case series* .

White Rose Research Online URL for this paper:
<http://eprints.whiterose.ac.uk/244/>

Article:

Walker, A., Brenchley, J., Sloan, J.P. et al. (2 more authors) (2004) Ultrasound by emergency physicians to detect abdominal aortic aneurysms: a UK case series. *Emergency Medicine Journal*, 21 (2). pp. 257-259. ISSN 1472-0213

<https://doi.org/10.1136/emj.2002.002121>

Reuse

Unless indicated otherwise, fulltext items are protected by copyright with all rights reserved. The copyright exception in section 29 of the Copyright, Designs and Patents Act 1988 allows the making of a single copy solely for the purpose of non-commercial research or private study within the limits of fair dealing. The publisher or other rights-holder may allow further reproduction and re-use of this version - refer to the White Rose Research Online record for this item. Where records identify the publisher as the copyright holder, users can verify any specific terms of use on the publisher's website.

Takedown

If you consider content in White Rose Research Online to be in breach of UK law, please notify us by emailing eprints@whiterose.ac.uk including the URL of the record and the reason for the withdrawal request.



eprints@whiterose.ac.uk
<https://eprints.whiterose.ac.uk/>

Ultrasound by emergency physicians to detect abdominal aortic aneurysms: a UK case series

A Walker, J Brenchley, J P Sloan, M Lalanda, H Venables

Emerg Med J 2004;21:257-259. doi: 10.1136/emj.2002.002121

Early identification of abdominal aortic aneurysms in some patients can be difficult and the diagnosis is missed in up to 30% of patients. Ultrasound cannot be used to identify a leak, but the presence of an aneurysm in an unstable patient is conclusive. With minimal training emergency physicians can easily identify the aorta and thus in the early phase of resuscitation an aneurysm can be confidently excluded. The purpose of the examination is not to delineate the extent of the aneurysm, but to identify those patients that will need emergency surgery. A series of patients presented to the department in an unstable condition with equivocal abdominal signs. An ultrasound scan in the resuscitation room by members of the emergency department revealed an aneurysm, which was enough to convince the vascular surgeons to take the patient straight to theatre with good results. In patients who are stable, computed tomography will continue to be used to evaluate the extent of the aneurysm and identify a leak.

Abdominal aortic aneurysms (AAA) present an important diagnostic challenge to emergency physicians. Although not a common condition, they are associated with significant mortality and early diagnosis is essential.

The diagnosis may be difficult in the emergency situation as patients may present with a non-specific history, and staff need a high index of suspicion to consider AAA in the differential diagnosis.¹ Computed tomography is the gold standard investigation but can lead to a delay in definitive diagnosis and treatment (especially out of normal working hours), and transfer to scan may be associated with further risks or deterioration. An early ultrasound scan in the resuscitation phase may be the primary investigation of choice.

Some departments have protocols whereby patients who are suspected of having a AAA are transferred directly to a vascular surgery centre for definitive diagnosis and treatment.

This may entail inappropriate patients being transferred, or delays at the presenting hospital if inexperienced medical staff require senior backup to make this decision.

Ultrasonography is routinely used for screening and monitoring of aneurysm diameter² and a limited ultrasound scan can reliably record the presence of an AAA.

If a normal aorta is clearly seen (as in most cases) an aneurysm can be confidently excluded. In the emergency setting no attempt is made to define the limits or relations of the aneurysm.

Ultrasound is not accurate in determining the presence of a leak from the aneurysm. In one study in emergency department patients, sonography was accurate in demonstrating presence or absence of aneurysm (98%), but its sensitivity for extraluminal blood was poor (4%).³

The combination of an aneurysm on ultrasound and an unstable patient is enough to warrant an emergency vascular surgery opinion.

PRINCIPLES OF EMERGENCY ULTRASOUND

Ultrasound use by emergency physicians is a focused examination to answer a single clinical question. In the assessment of trauma patients the purpose of the FAST (focused assessment with sonography in trauma) scan is to identify (rule in) the presence of free intraperitoneal fluid. In the context of trauma, this is assumed to be blood. Further management decisions are made according to the patient's condition, but ultrasound adds valuable information in the early stages of assessment.

TRAINING

All middle grade and senior emergency physicians at Leeds General Infirmary had previously been trained to use ultrasound in the evaluation of blunt abdominal trauma (FAST). This entailed two sessions of both didactic training on the principles of ultrasound and the FAST protocol, and practical experience on normal volunteers and simulated patients (peritoneal dialysis patient volunteers). Emergency physicians were then required to record scans on 10 normal volunteers, these were reviewed by expert sonographers before accreditation as an emergency physician sonographer.

Data from all scanned patients are routinely recorded and suggest that there is little skill attrition with time. Rotational middle grade staff have been trained in the technique and on return to the department months later continue to exhibit adequate sonography skills.

Trained emergency physician sonographers underwent a further session of training by expert sonographers. This included a review of aortic anatomy, demonstrations of normal ultrasound appearances, and review of AAA ultrasound appearance. Once trained, the emergency AAA scan could be performed in less than five minutes. The appearances of the normal aorta scan view are shown in figure 1.

CASE SERIES

We present a series of patients who have attended our emergency department over a six month period and had a provisional diagnosis of AAA.

All patients underwent an ultrasound scan performed by emergency physicians, and after discussion with the vascular surgeons were immediately transferred to theatre.

Case 1

A 65 year old man bent down to lift a box and felt pain in his left hip. On presentation to hospital, he was

Abbreviations: AAA, abdominal aortic aneurysms; FAST, focused assessment with sonography in trauma

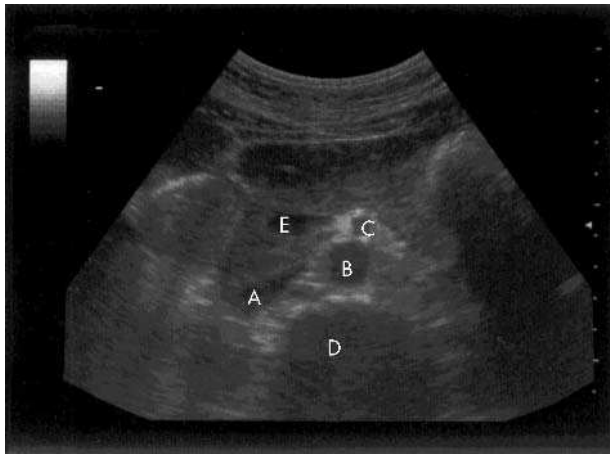


Figure 1 Normal anatomy (transverse). A, IVC; B, aorta; C, superior mesenteric artery; D, vertebral body; E, portal vein.

haemodynamically stable with a palpable AAA, confirmed on ultrasound. Shortly thereafter he became cardiovascularly unstable and was transferred to theatre for repair of an infra-renal AAA. He made a good recovery and was well six months later.

Case 2

A 72 year old man presented with abdominal and back pain. While in the emergency department he collapsed and the ultrasound scan in the resuscitation room demonstrated a 7 cm aneurysm. He was transferred to the operating theatre for repair and was well three months later.

Case 3 (fig 2)

A 69 year old man collapsed with abdominal pain and was brought to the emergency department. An ultrasound scan in the resuscitation room revealed a large AAA. He was transferred to operating theatre and is alive and well one year later.

Case 4

A 67 year old man had experienced abdominal and back pain overnight, in association with diarrhoea. He was hypotensive on arrival and a 7 cm AAA was discovered when an emergency physician performed ultrasound in the resuscitation room. He was transferred to the operating theatre and survived the repair but died three days after operation.

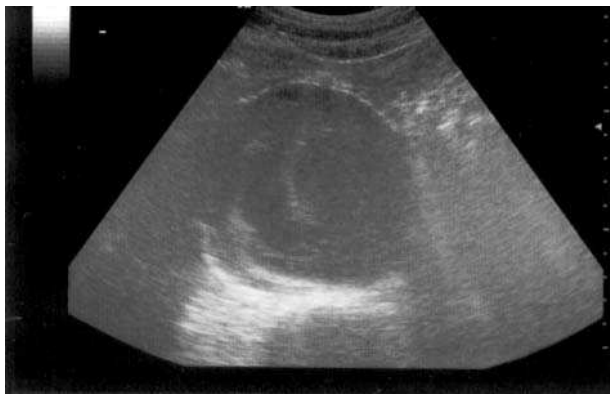

Figure 2 Case 2, 7 cm AAA.

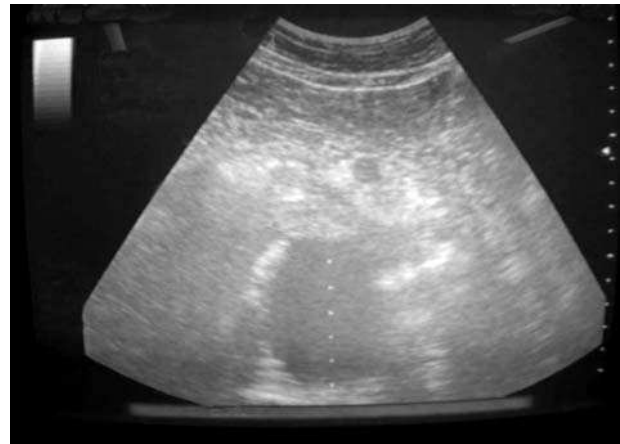

Figure 3 Case 5, 6 cm AAA.

Case 5 (fig 3)

A 58 year old man had colicky abdominal pain radiating to his back. He was haemodynamically stable and had an ultrasound scan performed as routine and to increase SHO awareness of the investigation. A 6 cm AAA was detected and he was referred for review by the vascular surgeons. Thirty minutes later he had a sudden haemodynamic collapse and was resuscitated and transferred straight to theatre.

These cases demonstrate the effectiveness of an emergency physician ultrasound scan in appropriate patients. Ultrasound has also been used successfully to exclude an AAA in hypotensive patients seen in the resuscitation room, and has therefore directed further investigations more appropriately. This is a small case series only looking at patients with positive scans. There is more work to be done evaluating the technique as rule out tool in these circumstances.

DISCUSSION

Some patients have a clear history and obvious clinical signs of an AAA. In these the diagnosis is not difficult. It has been clearly established that early diagnosis and surgery has significant survival benefits in these patients. An emergency physician performed ultrasound scan in the resuscitation room can be completed early while resuscitation is ongoing. Use of ultrasound by emergency physicians to exclude an AAA, is common in other countries.⁴

As increasing numbers of patients are transferred to a tertiary centre for surgery after acute presentation. A timely emergency physician performed ultrasound scan may expedite the decision to transfer.

Studies have shown that emergency physicians are accurate in the diagnosis of AAA on ultrasound. One study from Australia included patients in whom the diagnosis of AAA was suspected.⁵ Sixty eight scans were performed; 26 scans were positive, 40 scans yielded negative findings, and 2 scans were indeterminate. Scan interpretations were 100% accurate, compared with standard imaging or radiology review of the emergency ultrasound scan. In this study the primary benefit of ultrasonography was to exclude the diagnosis, but positive scans provided significant benefits for patients with AAA and led to improved management plans.

In our department, the use of ultrasound for AAA diagnosis followed naturally once the machine had been purchased by the department and emergency department staff had been trained in the FAST technique. The presence of an external aortic diameter of greater than 3 cm is considered

diagnostic of an AAA, although increasing size increases the risk of rupture.

Initially there were concerns voiced by radiology colleagues about the use of ultrasound by non-radiologists. Most vascular surgeons however, are familiar with the ultrasound appearances of AAA, and a consensus decision on further management was reached in the cases presented. In patients with leaking AAAs, the speed of transfer to definitive care is a significant prognostic factor, rapid access to a senior vascular surgical opinion may be expedited by the emergency physician ultrasound scan.

We have shown that ultrasound skills for specific limited indications are easily learnt and retained. Support of the local radiology department is invaluable in introducing ultrasound into the emergency department. In our department all scans were initially reviewed by expert sonographers and although there was some disagreement about scan quality, none of the clinical conclusions drawn was invalid. Hard copies of all scans were obtained for inclusion in the patient's notes and audit purposes. Ongoing review of a proportion of scans is worthwhile to monitor quality, this could be performed by an experienced emergency physician sonographer or radiology colleagues.

CONCLUSIONS

A limited ultrasound scan is a rapid screening test for detection of AAA in the resuscitation room. Emergency

physicians competent in other ultrasound techniques can reliably perform the technique after a short training programme

Authors' affiliations

A Walker, J P Sloan, M Lalanda, Department of Emergency Medicine, Leeds General Infirmary, Leeds, UK

J Brenchley, Department of Emergency Medicine, Barnsley District General Hospital, Barnsley, UK

H Venables, School of Healthcare Studies, University of Leeds, Leeds, UK

Correspondence to: Dr J Brenchley, Department of Emergency Medicine, Barnsley District General Hospital, Gawber Road, Barnsley S75 2EP, UK; jane.brenchley@bdgh-tr.trent.nhs.uk

Accepted for publication 7 March 2003

REFERENCES

- 1 Miller J, Miller J. Small ruptured abdominal aneurysm diagnosed by emergency physician ultrasound. *Am J Emerg Med* 1999;**17**:174-5.
- 2 Shuman WP, Hastrup W, Kohler TR, et al. Suspected leaking abdominal aortic aneurysm: use of sonography in the emergency room. *Radiology* 1988;**168**:117-19.
- 3 Goldberg BB. Aortosonography. *Int Surg* 1977;**62**:294-7.
- 4 Stahmer SA. Accident and emergency medicine. *BMJ* 1988;**316**:1071-4.
- 5 Kuhn M, Bonnin RL, Davey MJ, et al. Emergency department ultrasound scanning for abdominal aortic aneurysm: accessible, accurate, and advantageous. *Ann Emerg Med* 2000;**36**:219-23.

Bone marrow toxicity after yellow phosphorus ingestion

A J Tafur, J A Zapatier, L A Idrovo, J W Oliveros, J C Garces

Emerg Med J 2004;**21**:259-260. doi: 10/1136/emj.2003.007880

Suicidal ingestions of fireworks containing yellow phosphorus occur often during holidays. A case is reported of a 17 year old woman who intentionally ingested an estimated amount of 5.5 mg of yellow phosphorus, presenting with upper abdominal pain as the only complaint, a physical examination was normal. Blood tests showed a considerable decrease in the granulocyte count; the bone marrow biopsy revealed a decreased cellular mass with degenerative changes. Spontaneous remission was observed during the next 48 hours, with no further complaints.

Suicidal ingestions of round, penny sized fireworks known as *diablillos* are popular especially during the period of Christmas holiday. Each *diablillo* usually weighs 310 mg containing 2.4% of yellow phosphorus (YP), 39.4% of silica, and 50% of potassium chlorate.¹ The estimated lethal dose of YP is 1 mg/kg.² We present a case in which the ingestion of firework containing YP induced reversible bone marrow toxicity verified on biopsy examination.

CASE REPORT

A 17 year old woman, weighing 50 kg, was admitted to the emergency room after the intentional ingestion of three quarters of a *diablillo* nine hours before arrival (about 5.5 mg

of YP). Her vital signs were stable and the patient was conscious and well oriented. The chief complaint was upper abdominal pain and the rest of the physical examination was normal. There was no history of previous relevant illness. Gastric lavage was started with a solution containing potassium permanganate 1:1000; followed by activated charcoal and a mineral cathartic. Blood samples were obtained, and the analysis reported white blood cell (WBC) count 6.400/ μ l, red blood cell (RBC) count 3.9×10^6 / μ l, haemoglobin (Hb) 120 g/l, and platelet count 258 000/ μ l. Granulocyte count was 5900/ μ l. Hepatic and renal functions, as well as electrolytes were all normal. Intravenous fluids, and folic acid with iron supplementation were prescribed as support treatment.

After 24 hours in hospital, blood tests were repeated showing WBC 3.500/ μ l, RBC 3.73×10^6 / μ l, Hb 12.2 g/dl, platelet count 226.000/ μ l, and granulocytes decreased to 900/ μ l. A bone marrow biopsy was undertaken, and the histopathological analysis reported intense interstitial oedema, haemorrhages, and some necrotic foci. The morphology of the three cellular lines was normal, but the total cellular mass was at 50%. Neoplastic or fibrotic changes were not found; suggesting the diagnosis of unspecified degenerative toxic changes in the bone marrow (fig 1).

The patient remained stable and no complications appeared during her stay in hospital. Spontaneous resolution of the neutropenia was observed during the next 48 hours. The patient was discharged, and returned one month later for follow up presenting no further complains.