

This is a repository copy of *Dissociation of affective modulation of recollective and perceptual experience following amygdala damage*.

White Rose Research Online URL for this paper:

<https://eprints.whiterose.ac.uk/1447/>

Article:

Papps, BP, Calder, AJ, Young, AW orcid.org/0000-0002-1202-6297 et al. (1 more author) (2003) Dissociation of affective modulation of recollective and perceptual experience following amygdala damage. *Journal of Neurology, Neurosurgery and Psychiatry*. pp. 253-254. ISSN 0022-3050

<https://doi.org/10.1136/jnnp.74.2.253>

Reuse

Items deposited in White Rose Research Online are protected by copyright, with all rights reserved unless indicated otherwise. They may be downloaded and/or printed for private study, or other acts as permitted by national copyright laws. The publisher or other rights holders may allow further reproduction and re-use of the full text version. This is indicated by the licence information on the White Rose Research Online record for the item.

Takedown

If you consider content in White Rose Research Online to be in breach of UK law, please notify us by emailing eprints@whiterose.ac.uk including the URL of the record and the reason for the withdrawal request.



Dissociation of affective modulation of recollective and perceptual experience following amygdala damage

B P Papps, A J Calder, A W Young and R E O'Carroll

J. Neurol. Neurosurg. Psychiatry 2003;74;253-254
doi:10.1136/jnp.74.2.253

Updated information and services can be found at:
<http://jnp.bmjournals.com/cgi/content/full/74/2/253>

These include:

References

This article cites 20 articles, 4 of which can be accessed free at:
<http://jnp.bmjournals.com/cgi/content/full/74/2/253#BIBL>

2 online articles that cite this article can be accessed at:
<http://jnp.bmjournals.com/cgi/content/full/74/2/253#otherarticles>

Rapid responses

You can respond to this article at:
<http://jnp.bmjournals.com/cgi/eletter-submit/74/2/253>

Email alerting service

Receive free email alerts when new articles cite this article - sign up in the box at the top right corner of the article

Topic collections

Articles on similar topics can be found in the following collections

[Other Neurology](#) (3626 articles)
[Psychology](#) (382 articles)

Notes

To order reprints of this article go to:
<http://www.bmjournals.com/cgi/reprintform>

To subscribe to *Journal of Neurology, Neurosurgery, and Psychiatry* go to:
<http://www.bmjournals.com/subscriptions/>

SHORT REPORT

Dissociation of affective modulation of recollective and perceptual experience following amygdala damage

B P Papps, A J Calder, A W Young, R E O'Carroll

J Neurol Neurosurg Psychiatry 2003;**74**:253–254

It has been suggested that similar neural mechanisms may underlie the affective modulation of both recollective and perceptual experience. A case is reported of a patient who has bilateral amygdala damage and marked impairment in the perception of emotion, particularly fear. The patient DR and 10 healthy control subjects (matched for school leaving age, intelligence quotient, and non-emotional memory performance) were shown a series of slides accompanied by an emotionally arousing narrative. One week later DR and the controls were given a surprise memory test for this material. In addition, they completed a verbal memory test using emotionally arousing stimuli. Both DR and the healthy control subjects showed a normative pattern of enhanced memory for emotional material. On the basis of these results and the previously demonstrated impairment of perception of emotion in this patient, it is concluded that *different* neural mechanisms may underlie affective modulation of recollective and perceptual experience.

Anderson and Phelps¹ recently presented evidence suggesting that lesions of the amygdala impair enhanced perception of emotionally salient events. They proposed that "similar neural mechanisms may underlie the affective modulation of both recollective and perceptual experience" (p 305). We report the case of a patient "DR" (not her actual initials) who has bilateral amygdala damage, and who has marked impairment in the perception of emotion, particularly fear.^{2,3} Previous detailed neuropsychological test results on DR found no evidence of impairment of basic visual and auditory functions; however, she suffers from a marked impairment in recognising facial and vocal signals of fear, and to a lesser extent, anger.^{2,3} The purpose of this investigation was to test whether she would show similar deficits in memory for emotional material. If similar neural mechanisms underlie the affective modulation of memory and perception,¹ then she should show evidence of a deficit in emotional memory. We used an assessment of emotional memory functioning that is widely used in psychopharmacological investigations of the role of the adrenergic system in human subjects.^{4,7} The method for assessing memory for emotionally arousing material has also been shown to be sensitive to amygdala damage.⁸

METHODS

DR is a 58 year old right handed woman who underwent a series of stereotactic operations targeted at the left and right amygdala in an attempt to control her epilepsy. MRI scanning indicates an extensive lesion to the left medial amygdala affecting the basal nuclei and sparing the lateral nucleus. The damage extends throughout the rostro-caudal limits of the left amygdala, reaching the anterior horn of the left hippocampus. Associated damage extends dorsally beyond the amygdala involving part of the anterior commissure, lateral putamen, and external capsule.

In the right hemisphere, there is a small posteriorly placed lesion in the right anterior amygdaloid area.⁹

DR and 10 healthy controls subjects (matched for current and school leaving age and intelligence quotient) were shown a series of slides accompanied by an emotionally arousing narrative.¹⁰ The slide narrative presentation can be divided into the three phases. The first phase contains essentially emotionally neutral information relating to the protagonists, a mother and son leaving home to visit the father. Emotionally arousing information is introduced in phase two, where a car accident occurs and the boy is critically injured. The final phase deals with the aftermath of these events (the alternative arrangements that have to be made by the mother to collect her other child).

One week later DR and the controls, without warning, were given a four alternative forced choice recognition memory test consisting of between five and nine multiple choice questions per slide. In addition, DR and the controls completed a verbal memory test using emotionally arousing stimuli: the affective auditory verbal learning test (AAVLT).¹¹ Participants are read a series of 15 words five times. Each of these five trials contains the same 15 word list (infections, negative emotions, dangerous weapons, and so on). After each trial, participants are required to repeat back as many of the words as they can remember. Following the fifth trial, participants are read a list of 15 new "distracter" words and are required to recall as many of these as they can remember. The short term recall assessment involves participants attempting to recall as many words from the original five trial lists as possible. This recall test occurs immediately following the recall of the distracter word list. After a period of 20 minutes, participants are again required to recall as many of the original words as possible.

In addition to the test of memory for affective words, all subjects completed the California verbal learning test (CVLT).¹² The design of this test is similar to the AAVLT but it comprises of neutral words only. For the purposes of the current study, DR and the controls' recall of words over the first five recall trials for the AAVLT and the CVLT were compared.

RESULTS

Figure 1 shows the mean recognition memory scores on the emotional slide story memory test for the control participants and DR. The controls had the normative pattern of increased recognition memory performance for the middle, emotive phase of the story. This was confirmed by submitting the controls' recognition memory scores to a repeated measures analysis of variance investigating the effect of phase of story ($F(2,18) = 19.73, p < 0.01$). Figure 1 also shows that DR had the same normative pattern of enhanced recognition memory for the second emotional phase of the story presentation. There was no significant difference between her total score

Abbreviations: AAVLT, affective auditory verbal learning test; CVLT, California verbal learning test

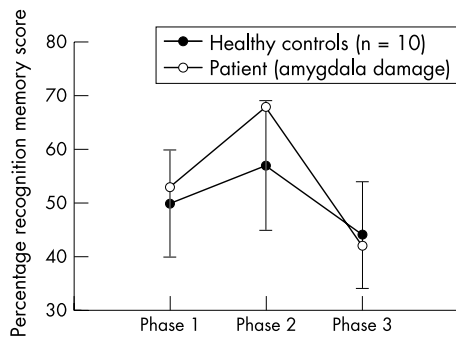


Figure 1 Long term recognition memory performance for emotional material. Recognition memory by phase of story, after a one week delay. Emotional content was introduced in phase 2.

(45) and the total score of the healthy controls (mean (SD), 61.1 (14.1)) on the total percentage correct over the first five recall trials on the neutral word memory task (CVLT, modified t test¹³: $t(9) = 1.09$, $p > 0.3$). Similarly, for the affective auditory verbal learning test,¹¹ an analysis of total percentage correct over five recall trials revealed no significant difference between the patient's total score (58), and the performance of the healthy controls (62.9 (13.3)) ($t(9) = 0.31$, $p > 0.7$).

DISCUSSION

Previous research has shown that damage to the human amygdala impairs emotionally enhanced declarative memory,^{14–16} and several functional imaging studies have implicated activation of the amygdala in the enhanced recall of emotional items.^{17–19} In comparison, the results of the current study demonstrate *preservation* of long term memory for emotional material in a patient with marked amygdala damage, who has previously been shown to have severe problems with the recognition of emotion, particularly fear.^{3,4} To our knowledge, this has not been shown before.

We began by noting that Anderson and Phelps have suggested that a similar neural mechanism underlies affective modulation of both recollective and perceptual experience.¹ While we do not have data on DR's performance on the attentional blink task used by those investigators, previous research has shown that her perception of facial and vocal signals of fear and anger is clearly abnormal. The evidence to date, then, shows a dissociation between higher level perceptual interpretation of emotion (including the ability to recognise facial expressions) and recall of emotional material. This strongly suggests that each is processed by separate neural systems.

One possible argument to the contrary would be to assume that the pattern of performance shown by DR resulted from partial damage to the system underlying both of these functions. In other words, limited damage to a single emotional system resulted in disruption of higher level perceptual interpretation, while residual and perhaps preserved "basic level" functioning was sufficient to allow subsequent memory for emotional material to remain intact. The extent of our patient's deficit in emotion perception remains to be fully explored. Nevertheless, her impaired recognition of fear is a robust and consistent effect that is evident across two tests of facial expression recognition³ and two tests of vocal expression recognition.⁴ In contrast, as we have discussed, she shows absolutely no evidence of impaired memory for emotionally arousing material as assessed using both the emotionally arousing slide show and the affective auditory verbal learning test.

DR's bilateral amygdala damage is incomplete (greater on the left); therefore it is entirely possible that different parts of the amygdala are involved in the mechanisms subserving emotional memory and emotion recognition. Indeed, functional imaging studies that have implicated the amygdala in

fearful face perception²⁰ show that coordinates of the maximal voxel in the structure are medial and ventral in facial emotion perception tasks. By contrast, amygdala coordinates associated with emotionally enhanced memory have been found to be more lateral and dorsal.¹⁹ These findings, and the results of the current study, are consistent with the view that the amygdala is not a unitary structure²¹ and that different regions subserve differing cognitive processes.

Authors' affiliations

B P Papps, Department of Psychology, Institute of Psychiatry, London, UK
A J Calder, MRC Cognition and Brain Sciences Unit, Cambridge, UK
A W Young, Department of Psychology, University of York, York, UK
R E O'Carroll, School of Psychology, University of St Andrews, Fife, Scotland, UK

Competing interests: none declared.

Correspondence to: Professor Ronan O'Carroll, School of Psychology, University of St Andrews, St Andrews, Fife KY16 9JU, Scotland, UK; ronan@st-and.ac.uk

Received 26 March 2002

In revised form 23 August 2002

Accepted 5 September 2002

REFERENCES

- Anderson AA, Phelps EA. Lesions of the human amygdala impair enhanced perception of emotionally salient events. *Nature* 2001;**411**:305–9.
- Calder AJ, Young AW, Rowland D, et al. Facial emotional recognition after bilateral amygdala damage: differentially severe impairment of fear. *Cogn Neuropsychol* 1996;**13**:699–745.
- Scott SK, Young AW, Calder AJ, et al. Impaired auditory recognition of fear and anger following bilateral amygdala lesions. *Nature* 1997;**385**:254–7.
- Cahill L, Prins B, Weber M, et al. β -Adrenergic activation and memory for emotional events. *Nature* 1994;**371**:702–4.
- O'Carroll RE, Drysdale E, Cahill L, et al. Stimulation of the noradrenergic system enhances and blockade reduces memory for emotional material in man. *Psychol Med* 1999;**29**:1083–8.
- van Stegeren AH, Everaerd W, Cahill L, et al. Memory for emotional events: differential effects of centrally versus peripherally acting β -blocking agents. *Psychopharmacology* 1998;**138**:305–10.
- Papps BP, Shajahan PM, Ebmeier KP, et al. The effects of noradrenergic re-uptake inhibition on memory encoding in man. *Psychopharmacology* 2002;**159**:311–18.
- Phelps EA, LaBar KS, Anderson AK, et al. Specifying the contributions of the human amygdala to emotional memory: a case study. *Neurocase* 1998;**4**:527–40.
- Young AW, Aggleton JP, Hellawell DJ, et al. Face processing impairments after amygdalotomy. *Brain* 1995;**118**:15–24.
- Cahill L, Babinsky R, Markowitsch HJ, et al. The amygdala and emotional memory. *Nature* 1995;**377**:295–6.
- Snyder KA, Harrison DW. The affective auditory verbal learning test. *Arch Clin Neuropsychol* 1997;**12**:477–82.
- Delis DC, Kramer JH, Kaplan E, et al. *California verbal learning test – adult version research manual*. San Antonio: The Psychological Corporation, 1987.
- Crawford JR, Howell DC. Comparing an individual's test score against norms derived from small samples. *Clin Neuropsychol* 1998;**12**:482–6.
- Adolphs R, Cahill L, Schul R, et al. Impaired declarative memory for emotional material following bilateral amygdala damage in humans. *Learning Memory* 1997;**4**:291–300.
- Adolphs R, Tranel D, Denburg N. Impaired emotional declarative memory following unilateral amygdala damage. *Learning Memory* 2000;**7**:180–6.
- Markowitsch HJ, Calabrese P, Wurker M, et al. The amygdalas contribution to memory: a study on 2 patients with Urbach-Wiethe disease. *Neuroreport* 1994;**5**:1349–52.
- Cahill L, Haier RJ, Fallon J, et al. Amygdala activity at encoding correlated with long-term free recall of emotional information. *Proc Natl Acad Sci USA* 1996;**93**:8016–21.
- Hamann SB, Ely TD, Grafton ST, et al. Amygdala activity related to enhanced memory for pleasant and aversive stimuli. *Nat Neurosci* 1999;**2**:289–93.
- Canli T, Zhao Z, Brewer J, et al. Event related activation in the human amygdala associates with later memory for individual emotional experience. *J Neurosci* 2000;**20**:RC99.
- Morris JS, Frith CD, Perrett DI, et al. A differential neural response in the human amygdala to fearful and happy facial expressions. *Nature* 1996;**383**:812–15.
- Petrovich GD. What is the amygdala? *Trends Neurosci* 1998;**21**:323–31.