



This is a repository copy of *In-vivo validity of proximal caries detection in primary teeth, with histological validation.*

White Rose Research Online URL for this paper:  
<https://eprints.whiterose.ac.uk/142647/>

Version: Accepted Version

---

**Article:**

Subka, S., Rodd, H., Nugent, Z. et al. (1 more author) (2019) In-vivo validity of proximal caries detection in primary teeth, with histological validation. *International Journal of Paediatric Dentistry*, 29 (4). pp. 429-438. ISSN 0960-7439

<https://doi.org/10.1111/ipd.12478>

---

This is the peer reviewed version of the following article: Subka, S. , Rodd, H. , Nugent, Z. and Deery, C. (2019), In-vivo validity of proximal caries detection in primary teeth, with histological validation. *Int J Paediatr Dent*, which has been published in final form at <https://doi.org/10.1111/ipd.12478>. This article may be used for non-commercial purposes in accordance with Wiley Terms and Conditions for Use of Self-Archived Versions.

**Reuse**

Items deposited in White Rose Research Online are protected by copyright, with all rights reserved unless indicated otherwise. They may be downloaded and/or printed for private study, or other acts as permitted by national copyright laws. The publisher or other rights holders may allow further reproduction and re-use of the full text version. This is indicated by the licence information on the White Rose Research Online record for the item.

**Takedown**

If you consider content in White Rose Research Online to be in breach of UK law, please notify us by emailing [eprints@whiterose.ac.uk](mailto:eprints@whiterose.ac.uk) including the URL of the record and the reason for the withdrawal request.



[eprints@whiterose.ac.uk](mailto:eprints@whiterose.ac.uk)  
<https://eprints.whiterose.ac.uk/>

**In-vivo validity of proximal caries detection in primary teeth, with histological validation**

S. Subka<sup>a</sup>, H.D. Rodd<sup>a</sup>, Z. Nugent<sup>b</sup>, C. Deery<sup>a</sup>.

a: School of Clinical Dentistry, University of Sheffield, UK.

b: Cancercare Manitoba, Manitoba, Canada.

**Short title: Evaluation of approximal caries detection**

**Key words:** Caries detection, Laser fluorescence, Radiographs, Temporary tooth separation, Visual examination, Histological validation

**Corresponding author:**

Samiya Subka  
School of Clinical Dentistry  
University of Sheffield  
Claremont Crescent  
Sheffield  
S10 2TA  
U.K.  
Email: [samiyasubka@gmail.com](mailto:samiyasubka@gmail.com)

## **Summary:**

**Background:** Detection and diagnosis of proximal caries in primary molars is challenging.

**Aim:** The aim of this *in-vivo* study was to assess the validity and reproducibility of four methods of proximal caries detection in primary molar teeth.

**Design:** Eighty-two children (5-10 yrs) were recruited. Initially 1030 proximal surfaces were examined using meticulous visual examination (ICDAS) (VE1), bitewing radiographs (RE), and a laser fluorescence pen device (LF1). Temporary tooth separation (TTS) was achieved for 447 surfaces and these were re-examined visually (VE2) and using the LF-pen (LF2). Three hundred and fifty-six teeth (542 surfaces) were subsequently extracted and provided histological validation.

**Results:** At D<sub>1</sub> (enamel and dentine caries) diagnostic threshold, the sensitivity of VE1, RE, VE2, LF1 and LF2 examination were 0.52, 0.14, 0.75, 0.58, 0.60 and the specificity values were 0.89, 0.97, 0.88, 0.85, 0.77 respectively. At D<sub>3</sub> (dentine caries) threshold, the sensitivity values were 0.42, 0.71, 0.49, 0.63, 0.65 respectively, while specificity was 0.93 for VE1 and VE2, and 0.98, 0.87 and 0.88 for RE, LF1 and LF2 examinations respectively. ROC analysis showed radiographic examination to be superior at D<sub>3</sub>.

**Conclusion:** Meticulous caries diagnosis (ICDAS) should be supported by radiographs for detection of dentinal proximal caries in primary molars.

## Introduction

Diagnosis of dental caries has always been problematic, especially the diagnosis of proximal caries where the lack of accessibility and visibility makes it more difficult to detect caries at its early stages. Early diagnosis is paramount to allow evidence-based interventions to prevent disease progression [1].

To date, most studies have focussed on the permanent dentition and those that have looked at the primary dentition tend to only include the occlusal surfaces. Similarly, because of the logistical difficulties of achieving an adequate sample of representative teeth, there are far more *in-vitro* studies [2, 3] than *in-vivo* ones [4, 5]. *In-vivo* studies with histological validation are clearly superior to *in-vitro* studies because, even when great care is taken, it is impossible to re-create the difficulties of the clinical examination, such as the presence of a tongue, gingiva, saliva and patient co-operation [6, 7].

A recent systematic review reported visual inspection to have good accuracy for visual inspection, which was further improved when used in conjunction with a detailed and validated index [8]. Meticulous caries diagnostic methods such as the International Caries Detection and Assessment System (ICDAS), meets this requirement, having been demonstrated to have high validity and reproducibility [6, 9-11].

Bitewing radiographs provide an additional diagnostic yield, especially for proximal caries, where direct visual examination is not possible [12]. However, bitewing radiographs show where the lesion is anatomically, in enamel or dentine, but do not confirm the presence of cavitation which is the threshold between operative and non-operative intervention. Traditionally, spread into dentine has been taken as the point at which restoration is required but this may happen before cavitation, the point at which prevention is no longer possible

[13]. Therefore, a diagnostic tool which identifies cavitation rather than lesion depth is required.

For these reasons temporary tooth separation (TTS) is used by some clinicians for the detection of proximal caries and this adjunct to visual examination has been shown to be useful in identifying dental caries in the proximal surfaces of permanent premolars and molars [14] and of primary molars [15].

A laser fluorescence device (LF pen, DIAGNOdent pen, Kavo Biberarch, Germany) was introduced specifically for the diagnosis of proximal caries. However, there is a paucity of research on the performance of the LF pen device in clinical settings. To date, no histological validated clinical study with a sample size calculation has been published to compare the validity of different diagnostic methods (visual examination, radiographic examination, TTS and LF pen examination) for the diagnosis of proximal caries in primary teeth.

Therefore, the aim of this study was to clinically assess the validity and reproducibility of different diagnostic methods for proximal caries detection in primary molar teeth.

## **Methods and Material**

### *1. Ethical approval and subject selection*

Ethical approval was obtained from the National Health Services Research Ethics Committee (NHS REC) (Reference 12/YH/0214) and from Sheffield Teaching Hospitals Research Governance Department (protocol number STH16301). All parents or guardians gave written consent and all young participants provided their assent to participate in the study.

This was a prospective *in-vivo* study. A sample size calculation was conducted using nomograms for calculation of sample size in diagnostic studies [16]. The sample size calculation was based on existing studies of the validity of the LF pen device where the sensitivity was found to vary from 0.65 in an *in-vivo* study [5] to 0.95 in an *in-vitro* study. Therefore, the sensitivity used for the sample size calculation was 0.80 (an average of both values). Because data were collected from the clinic, the disease prevalence used for the calculation was estimated at 0.8 (80%). The significance level used was  $p=0.05$ . The number of surfaces required to answer the research question was found to be 262 surfaces. It was estimated that 80 patients needed to be recruited, which made this study potentially larger than any previously conducted study, in this area.

Ninety children, aged 5-10 years, who attended the new patient assessment clinic in the Paediatric Dentistry Department of the Charles Clifford Dental Hospital, Sheffield, UK, with caries in one or more primary molars, requiring extraction of one or more teeth, and who required intra-oral bitewing radiographs as part of their clinical assessment, were invited to participate in the study. Of these, six failed to attend their appointments, one patient had urgent extractions before his second examination and one child proved too anxious to cope with an examination, giving an overall response rate of 91%. Thus, 82 children (mean age=6.4; SD=1.3 years) participated in the study, of which almost 80% were aged between 5 and 7 years.

Children had all proximal surfaces of primary molars examined to avoid selection bias. In total, 1225 surfaces were examined, of which 195 surfaces (16%) had frank cavitation, and therefore were excluded from subsequent analysis. Of those included in the final analysis, 447 surfaces were temporarily separated and 542 surfaces from 356 primary molars (mean=4.34 per child, SD=2.09) were histologically validated.

Surfaces were excluded if they had frank cavitation involving the marginal ridge, a large carious cavity on occlusal or smooth surfaces, a large occlusal or proximal restoration, absence of the adjacent tooth, the presence of enamel or dentine defects, or the presence of extensive non-carious tooth surface loss. One further exclusion criteria was the absence of left and right side digital bitewing radiographs taken as part of their new patient assessment when clinically indicated.

## *2. Examination methods*

All radiographs were taken by a qualified radiographer prior to clinical examination. The digital x-ray machine (Sirona Heliodont DS intraoral X-ray generator, Bensheim, Germany) was set to 60KV, 7mA and the exposure time was 0.08s. Digital sensor holders (Rinn, XCP-DS, New Zealand) were used and the focus to film distance was 40cm. Intra oral sensors (Durr VistaRay, Germany) were processed (Durr VistaScan, Germany). Images were examined on the clinic's computer screens at x5 magnification (AGFA Healthcare's IMPAX X-Ray Angio Analysis R1.0, Germany).

The diagnostic tests were carried out over two visits seven to 14 days apart by a trained and calibrated investigator (SS), in a fully equipped dental surgery. At the first visit, meticulous visual examination (ICDAS) (VE1) and the LF pen examinations (LF1) were conducted. Orthodontic separators (3M Unitek separator modules, US) were then placed between the primary molars which met the inclusion criteria. At the second visit, the two examination methods were repeated, after removal of the separators (VE2, LF2). The order of the examinations at each visit was selected randomly. The bitewing radiographs (RE) were scored on a separate occasion. The examiner was blind to the previous scores of the other examinations at all times, a nurse recorded the scores. A second examiner (CD) re-examined 10% of patients to assess the inter examiner reproducibility of the visual examination and re-

examined all the radiographs to determine the inter-examiner reproducibility of the radiographic examination.

Within the following three weeks all participants were scheduled for dental extractions under general anaesthesia in accordance with their initial treatment plan. The extracted teeth provided a full range of stages of disease for the following reasons. The teeth extracted usually had advanced caries in one proximal surface but no or less advanced caries on the other. Other teeth are extracted for balancing reasons and these teeth again provided sound or surfaces with initial caries, for analysis.

The examiner was trained in the use of the clinical, radiographic and histological codes and criteria by a person experienced in calibration for clinical, epidemiological and research studies (CD). Radiographs were interpreted using a modified Ekstrand criteria [17] (Table 1). This modification involved the splitting of code 2 (caries involving the inner half of enamel and outer third of dentine) into two codes, using the enamel dentinal junction as the dividing landmark. This approach permitted comparison with previous studies undertaken with the Ekstrand Criteria and traditional Downer criteria [18-21]. The examiner was trained and calibrated in the use of these criteria. Inter- and intra-examiner reproducibility were assessed. Kappa values for training were found to be 0.71 and 0.82 respectively.

Clinical examination was conducted using the ICDAS codes and criteria [9] (Table 1). The examiner was trained and calibrated in the use of these criteria and codes. The inter- and intra-examiner reproducibility of training was assessed by examining 10 randomly selected patients. The Kappa values were found to be  $K=0.79$  for both inter- and intra-examiner reproducibility.

The LF pen was used in accordance with the manufacturer's instructions using the probe tip 1. Proximal surfaces were assessed by inserting the probe tip underneath the contact area



from the buccal and the lingual/palatal aspects and moved until the peak value was recorded. The highest value of the two measurements (buccal and lingual insertion) was recorded and the zero value was then subtracted [21]. The number was shown on the digital screen as well as on the pen's screen and recorded by the dental nurse. The measurements were interpreted according to the manufacturer's instructions (Table 1). An expert from the Kavo Company (VM) trained the chief investigator on two occasions. The first session was conducted on extracted teeth and the second training session involved the use of the LF pen on patients after explanation and obtaining their consent. Involvement of participants, at different stages of the study, is shown in Figure 1.

### 3. *Histological validation*

After all examinations had been performed, 542 surfaces were available for the histological validation of the results obtained from the previous caries diagnostic tests. Figure 2 presents the number of tooth surfaces analysed at each stage of the study.

Extracted teeth were stored at -20°C in a locked laboratory until use. The mesial surface was then marked to aid identification of tooth surfaces after sectioning. Each tooth was serially sectioned in a mesio-distal direction using a water cooled band saw 0.2 mm thick (EXAKT-Apparatebau GmGH, Norderstedt, Germany) to achieve 5-8 cuts. Each section was approximately 500 µm thick. No teeth were lost during sectioning.

Each section was examined from both sides, by one of the authors (SS), under a magnification of x15 using a stereo-microscope. After scoring all the sections of each tooth, the highest score was given to the tooth surface. Digital images of histological sections were taken, and scoring was done on a computer screen independently by both examiners (SS and CD). The second examiner (CD) examined 10% of the histological sections to assess the inter-examiner reproducibility of the histological examination. The criteria proposed by

Ekstrand [17] were used. The same modification used for the radiographic criteria was also applied to these criteria (Table 1). The chief investigator was trained and calibrated in the use of these criteria. The Kappa value of training was 0.79.

#### 4. *Statistical analysis*

Validity of different diagnostic methods was assessed by calculating the sensitivity, specificity, positive predictive value, negative predictive value, likelihood ratios positive and negative, and the area under the receiver-operating characteristics (ROC) curves for each diagnostic method using the SAS 9.2 programme. Data were analysed at three diagnostic levels (D<sub>1</sub>, D<sub>3</sub> and ERK<sub>3</sub>). D<sub>1</sub>: D<sub>0</sub>= health, D<sub>1</sub>- D<sub>5</sub> = disease; D<sub>3</sub>: D<sub>0</sub>-D<sub>2</sub>= health, D<sub>3</sub>-D<sub>5</sub> = disease; ERK<sub>3</sub>: D<sub>0</sub>- D<sub>3</sub>= health; D<sub>4</sub>-D<sub>5</sub>= disease) (Table 1). The ROC comparisons were performed by using a contrast matrix to take differences of the areas under the empirical ROC curves [22]. IBM SPSS statistics 21 and SAS 9.2 programmes were used to analyse data. Simple descriptive analysis of all the variables was first conducted using SPSS statistics 21.

Inter- and intra-examiner reproducibility was assessed using the Kappa statistic (at D<sub>1</sub> and D<sub>3</sub> diagnostic thresholds).

## **Results**

The sample available for the histological validation consisted of 356 primary molars, of these 213 (60%) were first primary molars and 143 (40%) were second primary molars. The number of surfaces examined in each stage is shown in Figure 2. The initial visual examination (VE1), LF pen examination (LF1), and radiographic examination (RE) showed around 60% of surfaces to be sound. However, visual examination after TTS (VE2) and histological examination revealed more carious lesions, therefore, the number of sound surfaces declined in subsequent examinations. Table 2 presents the distribution of scores

from VE1, VE2, RE, LF1, LF2, and the histological assessment. The validity of different detection methods is shown in Table 3. In all cases the specificity was higher than the sensitivity.

At D<sub>1</sub> diagnostic threshold, meticulous visual examination after TTS (VE2) presented the highest sensitivity, positive predictive value, diagnostic accuracy and likelihood ratio positive. Radiographic examination showed the lowest sensitivity and the highest specificity of all examinations. The negative predictive values were relatively low for all examinations at the D<sub>1</sub> diagnostic threshold due to the high number of false negatives detected by these methods especially for radiographic examination where a large number of enamel carious lesions were scored as sound.

For the detection of dentine caries, radiographic examination showed the highest sensitivity and specificity of all examinations while visual examination demonstrated the lowest sensitivity. The LF pen (LF1) had higher sensitivity and lower specificity than visual examination (VE1).

Examining the areas under the ROC curve (Az) to compare the five methods a number of further findings can be seen (Table 4). Radiographic examination (RE) and TTS (VE2) significantly improved the validity of meticulous visual examination (VE1) at both diagnostic thresholds. However, there was no difference in the area under the curve at the D<sub>1</sub> diagnostic threshold and a superior validity at the D<sub>3</sub> diagnostic threshold when radiographs were compared with visual examination after TTS (VE2). The LF pen was not better than visual examination at the D<sub>3</sub> threshold but was superior at D<sub>1</sub> diagnostic threshold. Again the LF pen's performance was only better at D<sub>3</sub> when separation was used (LF2) in comparison to unseparated examination by the device (LF1). Radiographic examination was significantly more valid compared to all other methods at the D<sub>3</sub> diagnostic threshold. Of particular

interest is that radiographic examination was of equal validity to meticulous visual examination after TTS (VE2) at the D<sub>1</sub> diagnostic threshold and significantly better at the D<sub>3</sub> diagnostic threshold.

Histological examination showed perfect agreement between examiners at D<sub>1</sub> level and almost perfect agreement at D<sub>3</sub> level with a Kappa value of 0.87. All methods of examination showed good intra- and inter-examiner reproducibility ranging from substantial (0.73) to almost perfect (0.95) (Table 5).

## **Discussion**

Accurate detection and diagnosis of dental caries is fundamental to evidence-based care planning for children. It is important to first fully determine each child's caries risk status in order to devise an appropriate prevention and operative strategy. Early interventions are directed at arresting the caries process, and may obviate the need for restoration [1]. The benefits of this approach are obvious in reducing the burden of disease for children and their families, reducing potential stress for the clinician, and saving costs for health services.

This study is one of very few studies to look at the validity of diagnostic methods for the detection of proximal caries in primary teeth *in-vivo*, with histological validation and with a sample size calculation. The sample size calculation showed the need for 262 surfaces. Overall, the study sample provided 542 surfaces which were subject to histological validation for visual (VE1), radiographic (RE) and LF pen (LF1) examination. However, for those samples which were subject to visual examination and LF pen examination after temporary tooth separation (VE2, LF2), 237 and 226 surfaces respectively were validated histologically. The sample size calculations were based on a carious prevalence including code 6 lesions (n=142). However, these surfaces were subsequently excluded because these clearly identifiable large lesions inflate the sensitivity. If these surfaces had been included the sample

size would have exceeded the sample size required. Therefore, the results for all diagnostic methods are valid.

This study used a full mouth testing approach rather than pre-selecting sites, surfaces or teeth to experimental testing, which avoids the biases inherent in this latter approach and matches much more closely the real life situation [15, 23, 24]. Also the investigator was blind to which teeth had been treatment planned for extraction, thereby reducing any potential bias. However, this protocol made it impossible to obtain equal numbers of surfaces at all stages. In addition, in the case of TTS, if the child lost or removed the separators, the data would be lost in the present study. In contrast, in other studies, the investigators reinserted the separators and brought the patient back for a third visit in order to obtain the necessary data [5, 23, 24].

For the detection of enamel caries, visual examination after TTS was found to have superior validity. The use of separation helped the visual detection of white lesions which could not be detected by other methods, hence, were diagnosed as false negatives leading to low negative predictive values of these methods at D<sub>1</sub> level. However, all methods had high positive predictive values showing that they are good at confirming the presence of the disease.

Radiographic examination had the lowest sensitivity at the (D<sub>1</sub>) level of diagnosis which agrees with the findings of previous studies [5, 15, 23]. Although histological examination showed 35% of surfaces to have enamel caries, radiographic examination showed only 11% of the surfaces to have enamel caries which shows that radiographic examination was only able to detect less than one third of the enamel lesions. A systematic review of the validity of methods for the detection of non-cavitated carious lesion has also shown radiographic examination to have poor results for the detection of these lesions [25]. It also had a

likelihood ratio close to 1 indicating that the method is the least valuable for showing the absence of the disease at enamel diagnostic threshold.

ROC comparison of the different methods assessed in this study showed radiographic examination to be only better than visual examination (VE1) for the detection of proximal caries at the D<sub>1</sub> level. Visual examination with TTS (VE2) and the LF pen (LF1) were both similar to radiographic examination at this level of diagnosis.

For the detection of dentine caries, radiographic examination has been shown to have the highest sensitivity of all the diagnostic methods, which agrees with the findings of Novaes and colleagues [5], but disagrees with the findings of Shoaib et al [6] and Braga et al [3] who found the visual examination to be better than radiographic examination for the detection of proximal caries. Their findings [3, 6] may be attributed to the fact that their study was *in-vitro* and it is impossible to simulate the *in-vivo* settings *in-vitro*. Visibility and mobility of the proximal surfaces is always higher *in-vitro* than *in-vivo*. In the present study, ROC comparison showed radiographic examination to be significantly better than the other methods at this threshold.

The LF pen showed a trend for better performance at a more advanced threshold, consistent with findings from previous studies on the LF pen in proximal surfaces [5, 23, 26]. The specificity of the LF pen was higher than the sensitivity for all thresholds which agrees with other studies conducted in primary teeth [27]. Although the LF pen had higher sensitivity than visual examination at the D<sub>3</sub> threshold, its specificity was lower than that for visual examination at the same level of diagnosis. Therefore, the ROC comparison of the two methods showed no difference in the performance of both methods at the D<sub>3</sub> threshold. It was felt during the clinical examination that the insertion of the LF pen head between the teeth was difficult due to the tight and wide contacts. Therefore, it was assumed that TTS would

improve the validity of the LF pen examination. These results showed TTS to improve the performance of the LF pen at D<sub>3</sub> level only. However, for visual examination, the validity was improved at both levels of diagnosis. This agrees with the findings of a recent study (Ribeiro et al, 2015).

This is the first study to use histological examination (gold standard) for the validation of the findings. The obvious limiting factor with histological validation is that the tooth must be sectioned after examination in order to validate the results of the clinical examination. Experimental teeth must therefore be collected following extraction or physiological exfoliation. Clearly unless clinically indicated, it would be unethical to extract teeth purely for research purposes, and the problem with awaiting natural exfoliation is that there is no control over the time period between the examination and exfoliation. The *in-vivo* study of Rocha and colleagues [28] utilised teeth which had exfoliated up to 45 days after they had been tested with the LF pen and Ribeiro and colleagues [15] have also utilised teeth which had exfoliated up to two months after the last examination. It is argued that during this time period caries could have progressed leading to an underestimation of lesion size by the method used for examination, also using teeth close to exfoliation may not represent findings in the general population. While this may be unlikely in this short interval, investigators should bear in mind the rapid progression rate of some carious lesions in primary teeth which may reduce the sensitivity of the method assessed if there is an extended time lapse between examination and subsequent collection of the tooth sample. To avoid this potential problem, all patients in the present study were booked for their dental GA by the investigator. This ensured that tooth extractions occurred expediently following caries diagnosis; the time between initial examination and tooth collection was usually in the order of 2-3 weeks.

Most studies which have previously assessed the validity of caries diagnostic approaches have presented findings in terms of sensitivity and specificity. A recent systematic review of

methods for caries detection found that only five studies reported predictive values (positive and negative), and only three studies reported likelihood ratios [29]. Reference was therefore made to the Cochrane handbook for systematic reviews of Diagnostic Test Accuracy (DTA), which stipulates the standards which should be considered when analysing the quality of diagnostic studies (<http://www.cochrane.org/handbook>). Thus all appropriate tests recommended by the DTA, which included predictive positive and negative values and the likelihood ratios, have been reported in the present study. However, an acknowledged limitation is that the results are based on the examination of only one trained and calibrated examiner. A second limitation is that the study did not consider the concepts of activity, only considered the extension of caries.

**In conclusion**, this study is unique in that it is the only adequately powered study to examine the diagnosis of proximal caries in primary teeth with histological validation, using meticulous caries diagnosis (ICDAS), radiographs, LF pen and TTS.

The results of this study are complicated but the simple message is:

Although all diagnostic methods offered some benefit in specific clinical situations, preventive practice would be facilitated by the adoption of ICDAS supported by TTS as this had the highest sensitivity for the identification of D1 caries lesions. For the identification of D3 lesions, ICDAS must be supported by bitewing radiographs as they had the best performance for the detection of lesions in to dentine.

**Why this paper is important to Paediatric Dentistry:**

- This is the first adequately powered clinical study to examine the detection and diagnosis of caries in primary teeth with accompanying histological validation.
- The findings highlight that clinical visual examination alone is not able to detect all proximal caries in primary teeth.



- The study has important clinical relevance by confirming that temporary tooth separation was the best method for the detection of enamel caries while radiographs were superior for the detection of dentine caries in proximal surfaces of primary teeth.

**Acknowledgements:** We would like to thank Dr Halla Zaitoun for her assistance with participant recruitment and the collection of the study teeth. This study was undertaken while S.S. was a postgraduate student, whose studies were sponsored by the Libyan Ministry of Education. The funders had no role in study design, data collection and analysis, decision to publish, or preparation of the manuscript.

**Declaration of interest:** The authors declare that there are no potential conflicts of interest.

**Roles of all author:** CD conceived the idea, SS HDR CD developed the protocol, SS HDR CD data collection, ZN statistical analysis, SS, HDR, ZN CD writing of manuscript.

## References

- 1 Deery C. Caries detection and diagnosis, sealants and management of the possibly carious fissure. *Br Dent J.* 2013; **214**: 551-557.
- 2 Bittar DG, Gimenez T, Morais CC, De Benedetto MS, Braga MM, Mendes FM. Influence of moisture and plaque on the performance of a laser fluorescence device in detecting caries lesions in primary teeth. *Lasers Med Sci.* 2012; **27**: 1169-1174.
- 3 Braga MM, Morais CC, Nakama RCS, Leamari VM, Siqueira WL, Mendes FM. In vitro performance of methods of approximal caries detection in primary molars. *Oral Surg Oral Med Oral Pathol Oral Radiol Endod.* 2009; **108**: E35-E41.
- 4 Chen J, Qin M, Ma W, Ge L. A clinical study of a laser fluorescence device for the detection of approximal caries in primary molars. *Int J Paediatr Dent.* 2012; **22**: 132-138.
- 5 Novaes TF, Matos R, Braga MM, Imparato JCP, Raggio DP, Mendes FM. Performance of a Pen-Type Laser Fluorescence Device and Conventional Methods in Detecting Approximal Caries Lesions in Primary Teeth - in vivo Study. *Caries Res.* 2009; **43**: 36-42.
- 6 Shoaib L, Deery C, Ricketts DNJ, Nugent ZJ. Validity and Reproducibility of ICDAS II in Primary Teeth. *Caries Res.* 2009; **43**: 442-448.
- 7 Gimenez T, Piovesan C, Braga MM et al. Clinical relevance of studies on the accuracy of visual inspection for detecting caries lesions: a systematic review. *Caries Res.* 2015; **49**: 91-98.
- 8 Gimenez T, Piovesan C, Braga M et al. Visual inspection for caries detection: a systematic review and meta-analysis. *J Dent Res.* 2015; **94**: 895-904.
- 9 Ismail AI, Sohn W, Tellez M et al. The International Caries Detection and Assessment System (ICDAS): an integrated system for measuring dental caries. *Community Dent Oral Epidemiol.* 2007; **35**: 170-178.

- 10 Jablonski-Momeni A, Stachniss V, Ricketts DN, Heinzl-Gutenbrunner M, Pieper K. Reproducibility and accuracy of the ICDAS-II for detection of occlusal caries in vitro. *Caries Res.* 2008; **42**: 79-87.
- 11 Ekstrand KR, Gimenez T, Ferreira FR, Mendes FM, Braga MM. The International Caries Detection and Assessment System–ICDAS: A Systematic Review. *Caries Res.* 2018; **52**: 406-419.
- 12 Hopcraft MS, Morgan MV. Comparison of radiographic and clinical diagnosis of approximal and occlusal dental caries in a young adult population. *Community Dent Oral Epidemiol.* 2005; **33**: 212-218.
- 13 Ratledge D, Kidd E, Beighton D. A clinical and microbiological study of approximal carious lesions. *Caries Res.* 2001; **35**: 3-7.
- 14 Deery C, Care R, Chesters R, Huntington E, Stelmachonoka S, Gudkina Y. Prevalence of dental caries in Latvian 11-to 15-year-old children and the enhanced diagnostic yield of temporary tooth separation, FOTI and electronic caries measurement. *Caries Res.* 2000; **34**: 2-7.
- 15 Ribeiro AA, Purger F, Rodrigues JA et al. Influence of contact points on the performance of caries detection methods in approximal surfaces of primary molars: an in vivo study. *Caries Res.* 2015; **49**: 99-108.
- 16 Jones SR, Carley S, Harrison M. An introduction to power and sample size estimation. *Emerg Med J.* 2003; **20**: 453-458.
- 17 Ekstrand KR, Ricketts DNJ, Kidd EAM. Reproducibility and accuracy of three methods for assessment of demineralization depth on the occlusal surface: An in vitro examination. *Caries Res.* 1997; **31**: 224-231.

- 18 Mendes FM, Hissadomi M, Imparato JCP. Effects of drying time and the presence of plaque on the in vitro performance of laser fluorescence in occlusal caries of primary teeth. *Caries Res.* 2004; **38**: 104-108.
- 19 Deery C, Iloya J, Nugent ZJ, Srinivasan V. Effect of placing a clear sealant on the validity and reproducibility of occlusal caries detection by a laser fluorescence device: An in vitro study. *Caries Res.* 2006; **40**: 186-193.
- 20 Lussi A, Hack A, Hug I, Heckenberger H, Megert B, Stich H. Detection of approximal caries with a new laser fluorescence device. *Caries Res.* 2006; **40**: 97-103.
- 21 Rodrigues JA, Diniz MB, Josgrilberg EB, Cordeiro RCL. In vitro comparison of laser fluorescence performance with visual examination for detection of occlusal caries in permanent and primary molars. *Lasers Med Sci.* 2009; **24**: 501-506.
- 22 DeLong ER, DeLong DM, Clarke-Pearson DL. Comparing the Areas under Two or More Correlated Receiver Operating Characteristic Curves: A Nonparametric Approach. *Biometrics.* 1988; **44**: 837-845.
- 23 Novaes TF, Matos R, Raggio DP, Imparato JCP, Braga MM, Mendes FM. Influence of the Discomfort Reported by Children on the Performance of Approximal Caries Detection Methods. *Caries Res.* 2010; **44**: 465-471.
- 24 Mendes FM, Novaes T, Matos R et al. Radiographic and laser fluorescence methods have no benefits for detecting caries in primary teeth. *Caries Res.* 2012; **46**: 536-543.
- 25 Gomez J, Ellwood RP, Martignon S, Pretty IA. Dentists' perspectives on caries-related treatment decisions. *Community Dent Health.* 2014; **31**: 91-98.
- 26 Lussi A, Hellwig E. Performance of a new laser fluorescence device for the detection of occlusal caries in vitro. *J Dent.* 2006; **34**: 467-471.

- 27 Gimenez T, Braga MM, Raggio DP, Deery C, Ricketts DN, Mendes FM. Fluorescence-Based Methods for Detecting Caries Lesions: Systematic Review, Meta-Analysis and Sources of Heterogeneity. *PLoS One*. 2013; **8**: e60421.
- 28 Rocha RO, Ardenghi TM, Oliveira LB, Rodrigues C, Ciamponi AL. In vivo effectiveness of laser fluorescence compared to visual inspection and radiography for the detection of occlusal caries in primary teeth. *Caries Res*. 2003; **37**: 437-441.
- 29 Gomez J, Tellez M, Pretty IA, Ellwood RP, Ismail AI. Non-cavitated carious lesions detection methods: a systematic review. *Community Dent Oral Epidemiol*. 2013; **41**: 54-66.

Table 1. The relationship between the histological scores and the clinical codes and criteria at each level of diagnosis.

Table 2. The distribution of scores from VE1, VE2, RE, LF1, LF2, and for the histology.

Table 3. The diagnostic parameters of the examination methods used at three levels of diagnosis







Table 4. Comparison of areas under the ROC for different detection methods of proximal caries in primary teeth

Table 5. Intra- and inter-examiner reproducibility of the proximal caries detection methods in primary molars

Figure 1. Study flowchart showing the general outline of the research study.

Figure 2. The number of tooth surfaces histologically validated for each diagnostic examination

**Table 1** The relationship between the histological scores and the codes and criteria of clinical examination, radiographic examination and the LF pen at each level of diagnosis.

Histological section	Histological Score	ICDAS score (visual)	RE score	LF pen score	Level of analysis
	Score 0, no enamel demineralisation	0 Sound tooth surface	0	0-7	Sound
	Score 1 demineralization in the outer half of enamel	1 visual change seen after air drying	1	8-15	D <sub>1</sub>
	Score 2 demineralisation extending to the inner half of enamel	2 white or brown discoloration of enamel seen without air drying	2		
	Score 3 demineralisation in the outer one third of dentine	3, micro cavitation of enamel surface 4, intact surface with underlying shadow	3	≥16	D <sub>3</sub>
	Score 4 demineralisation extending to the middle third of dentine		4		ERK <sub>3</sub>
	Score 5 demineralisation extending to the inner third of dentine	5, 6 Cavitation	5		

RE=radiographic examination, LF pen=laser fluorescence pen, D<sub>1</sub>: D<sub>0</sub>= health, D<sub>1</sub>- D<sub>5</sub> = disease; D<sub>3</sub>: D<sub>0</sub>-D<sub>2</sub>= health, D<sub>3</sub>-D<sub>5</sub> = disease; ERK<sub>3</sub>: D<sub>0</sub>- D<sub>3</sub>= health; D<sub>4</sub>-D<sub>5</sub>= disease

**Table 2** The distribution of scores from VE1, VE2, RE, LF1, LF2, and for the histology.

Score	VE1		VE2		RE		LF pen1		LFpen2		Histology	
	(N)	(%)	(N)	(%)	(N)	(%)	(N)	(%)	(N)	(%)	(N)	(%)
<b>0</b>	649	63	166	37.1	600	58.5					118	21.7
<b>1</b>	22	2.1	17	3.8	79	7.7					60	11
<b>2</b>	175	17	161	36	65	6.3					133	24.5
<b>3</b>	11	1.1	10	2.2	155	15					61	11.2
<b>4</b>	63	6.1	20	4.5	62	6.0					36	6.6
<b>5</b>	110	10.7	73	16.3	42	4.1					134	24.7
<b>Not seen</b>					27	2.1						
<b>D<sub>0</sub></b>							603	58.3	207	49.6		
<b>D<sub>1</sub></b>							137	7.7	68	16.3		
<b>D<sub>3</sub></b>							290	28.2	142	34.7		
<b>Total</b>	1030	100	474	100	1030	100	1030	100	417	100	542	100

VE2= visual examination after TTS, LF pen 2= LF pen examination after TTS, RE=radiographic examination, D<sub>1</sub>: D<sub>0</sub>= health, D<sub>1</sub>- D<sub>5</sub> = disease; D<sub>3</sub>: D<sub>0</sub>-D<sub>2</sub>= health, D<sub>3</sub>-D<sub>5</sub> = disease



**Table 3** The diagnostic parameters of the examination methods used at three levels of diagnosis

	<b>VE1</b>	<b>VE2</b>	<b>RE</b>	<b>LF pen1</b>	<b>LF pen2</b>
<b>Sensitivity</b>					
D <sub>1</sub>	0.52	0.75	0.14	0.58	0.60
D <sub>3</sub>	0.43	0.49	0.71	0.63	0.65
ERK <sub>3</sub>	0.55	0.63	0.86	0.71	0.77
<b>Specificity</b>					
D <sub>1</sub>	0.89	0.88	0.97	0.85	0.77
D <sub>3</sub>	0.93	0.93	0.98	0.87	0.88
ERK <sub>3</sub>	0.93	0.90	0.94	0.83	0.81
<b>PVP (%)</b>					
D <sub>1</sub>	94	97	95	93	94
D <sub>3</sub>	82	88	96	78	84
ERK <sub>3</sub>	77	77	88	65	66
<b>PVN (%)</b>					
D <sub>1</sub>	34	35	25	36	24
D <sub>3</sub>	69	65	82	76	72
ERK <sub>3</sub>	82	83	94	87	88
<b>DV</b>					
D <sub>1</sub>	60	77	33	64	63
D <sub>3</sub>	72	72	87	77	76
ERK <sub>3</sub>	81	81	92	79	80
<b>LR +ve</b>					
D <sub>1</sub>	4.69	6	5.41	3.82	2.67
D <sub>3</sub>	6.39	7.37	35.67	4.86	5.30
ERK <sub>3</sub>	7.64	6.6	15.37	4.13	4.2
<b>LR -ve</b>					
D <sub>1</sub>	0.54	0.29	0.88	0.49	0.51
D <sub>3</sub>	0.61	0.54	0.30	0.43	0.40
ERK <sub>3</sub>	0.48	0.41	0.15	0.35	0.29
<b>Az (95% confidence limits)</b>					
D <sub>1</sub>	0.70 (0.67-0.74)	0.83 (0.77-0.88)	0.75 (0.72-0.78)	0.78(0.74-0.82)	0.70 (0.61-0.79)
D <sub>3</sub>	0.76 (0.72-0.79)	0.80 (0.75-0.85)	0.89 (0.87-0.92)	0.83 (0.80-0.87)	0.83 (0.78-0.88)
ERK <sub>3</sub>	0.79 (0.75-0.83)	0.80 (0.74-0.86)	0.92 (0.89-0.95)	0.86 (0.83-0.89)	0.83 (0.77-0.89)

PVP=Predictive value positive, PVN=Predictive value negative, DV=Diagnostic value, LR=Likelihood ratio, Az=Area under the ROC. D<sub>1</sub>: D<sub>0</sub>= health, D<sub>1</sub>- D<sub>5</sub> = disease; D<sub>3</sub>: D<sub>0</sub>-D<sub>2</sub>= health, D<sub>3</sub>-D<sub>5</sub> = disease; ERK<sub>3</sub>: D<sub>0</sub>- D<sub>3</sub>= health; D<sub>4</sub>-D<sub>5</sub>= disease

**Table 4** Comparison of areas under the ROC for different detection methods of proximal caries in primary teeth.

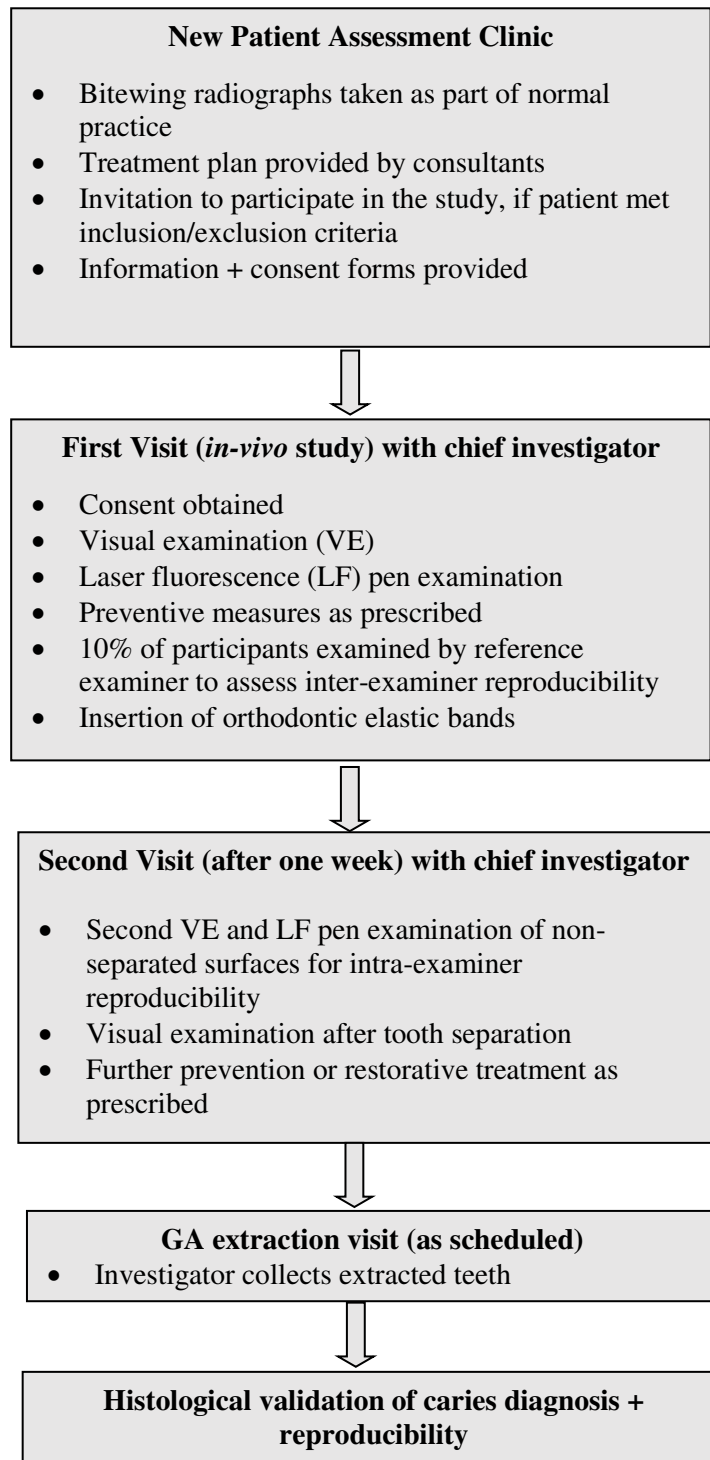
<b>Detection methods compared</b>	At D <sub>1</sub> diagnostic level		At D <sub>3</sub> diagnostic level	
	<b>Difference</b>	<b>P value</b>	<b>Difference</b>	<b>P value</b>
VE1 x VE2	VE2 > VE1	<0.01	VE2 > VE1	<0.01
VE1 x LF1	LF1 > VE1	<0.01	No difference	0.09
VE1 x RE	RE > VE1	0.04	RE > VE1	<0.01
LF1 x RE	No difference	0.60	RE > LF1	<0.01
LF1 x LF2	No difference	0.36	LF2 > LF1	0.02
VE2 x LF1	No difference	0.72	No difference	0.25
VE2 x RE	No difference	0.60	RE > VE2	<0.01
VE2 x LF2	VE2 > LF2	0.01	No difference	0.432

VE1=visual examination before temporary tooth separation, LF1=LF pen examination before temporary tooth separation, RE=radiographic examination, VE2=visual examination after temporary tooth separation, LF2=LF pen examination after temporary tooth separation

**Table 5** Intra- and inter-examiner reproducibility of the proximal caries detection methods in primary molars

Examination method	Kappa value (95% CI)	
	D <sub>1</sub>	D <sub>3</sub>
<b>Intra-examiner</b>		
<b>Visual examination</b>	0.76 (0.70-0.81)	0.83 (0.77-0.89)
<b>Radiographic examination</b>	0.91 (0.84-0.98)	0.95 (0.89-1)
<b>LF pen examination</b>	0.75 (0.70-0.79)	0.77 (0.72-0.82)
<b>Histological examination</b>	1 (1-1)	0.88 (0.77-0.99)
<b>Inter-examiner</b>		
<b>Visual examination</b>	0.76 (0.60-0.91)	0.85 (0.71-0.99)
<b>Radiographic examination</b>	0.73 (0.69-0.77)	0.79 (0.76-0.83)
<b>Histological examination</b>	1 (1-1)	0.87 (0.76-0.99)

Figure 2. Study flowchart showing the general outline of the research study.



**Figure 2. The number of tooth surfaces analysed at each stage of the study.**

