



This is a repository copy of *Investigation into surface interaction between the contact lens, the upper eyelid and cornea using optical coherence tomography*.

White Rose Research Online URL for this paper:

<https://eprints.whiterose.ac.uk/134817/>

Version: Accepted Version

---

**Proceedings Paper:**

Morecroft, R., Carre, M.J. [orcid.org/0000-0003-3622-990X](https://orcid.org/0000-0003-3622-990X), Lewis, R. [orcid.org/0000-0002-4300-0540](https://orcid.org/0000-0002-4300-0540) et al. (5 more authors) (2017) Investigation into surface interaction between the contact lens, the upper eyelid and cornea using optical coherence tomography. In: *Optical Fibers and Sensors for Medical Diagnostics and Treatment Applications XVII*; SPIE BIOS, 28 Jan - 02 Feb 2017, San Francisco, California, United States. SPIE . ISBN 978-1-5106-0558-9

<https://doi.org/10.1117/12.2250896>

---

**Reuse**

Items deposited in White Rose Research Online are protected by copyright, with all rights reserved unless indicated otherwise. They may be downloaded and/or printed for private study, or other acts as permitted by national copyright laws. The publisher or other rights holders may allow further reproduction and re-use of the full text version. This is indicated by the licence information on the White Rose Research Online record for the item.

**Takedown**

If you consider content in White Rose Research Online to be in breach of UK law, please notify us by emailing [eprints@whiterose.ac.uk](mailto:eprints@whiterose.ac.uk) including the URL of the record and the reason for the withdrawal request.



[eprints@whiterose.ac.uk](mailto:eprints@whiterose.ac.uk)  
<https://eprints.whiterose.ac.uk/>

# Investigation into surface interaction between the contact lens, the upper eyelid and cornea using optical coherence tomography

R. Morecroft<sup>a</sup>, M. J. Carré<sup>a</sup>, R. Lewis<sup>a</sup>, P. Mylon<sup>a</sup>, S. J. Matcher<sup>b</sup>, P. Toomey<sup>c</sup>, J. E. Goff<sup>d</sup> and R. Maiti<sup>\*a</sup>

<sup>a</sup>*Department of Mechanical Engineering, University of Sheffield, S1 4ET, UK*

<sup>b</sup>*Department of Electronic and Electrical Engineering, University of Sheffield, S3 7HQ, UK*

<sup>c</sup>*Ophthalmic Imaging, Royal Hallamshire Hospital, NHS Foundation Trust, Sheffield, S10 2JF, UK*

<sup>d</sup>*School of Science, Lynchburg College, Lynchburg, Virginia 24501, USA*

## ABSTRACT

**Background and Aim:** Over 50% of the total 125 million contact lens users complain of discomfort due to contact lenses. The aim of the project is to understand the effect of contact lenses on the morphological parameters of cornea and eyelid surfaces.

**Methods and results:** Five volunteers were recruited for this study (3 soft contact lens users and 2 non-users). The volunteers were imaged using a slit lamp and Optical Coherence Tomography (OCT) before and after a period of 6-7 hours. There was a significant increase in epidermal thickness of the eyelid for contact lens users compared to non-users. In addition, the upper eyelid roughness for contact lens users and non-users increased significantly. This might be due to deposition of particles from the eyelid during the wiping process.

**Conclusions:** Contact lens usage does affect the morphological parameters of eyelid. OCT is a powerful tool to measure these morphological changes in the eye. However, more volunteers must be recruited to get a better understanding of these changes.

**Keywords:** Anterior Segment Optical Coherence Tomography, Spectralis, Contact lens, Thickness, Roughness

## 1. INTRODUCTION

There are approximately 125 million contact lens users worldwide and of these users over 50% complain of some level of discomfort<sup>1,2</sup>. The discomfort experienced by contact lens users varies from dryness of the eye, irritation from the contact lens rubbing against the eye and eye infection. Redness might be influenced by allergies, pollution or even small airborne particles of dirt or dust deposited in the eye<sup>3</sup>. Typically, lens users find that lens comfort declines throughout the day and dryness and discomfort are the main reasons for discontinuation in contact lens usage<sup>4</sup>. Contact lens wear is generally safe and comfortable presuming contact lens users are compliant with contact lens care and usage instructions.

Optical Coherence Tomography (OCT) is an established non-invasive medical-imaging technique which utilizes near-infrared light to capture a reflectance profile of the sub-surface layers within skin. Previous studies on volar forearm skin have utilized the high axial resolution (~5-10 $\mu$ m) of OCT to delineate the dermal-epidermal junction (DEJ) within the skin, allowing for automated measurements of epidermal thickness<sup>5,6</sup>. Using OCT in the eye is very common in ophthalmology research, with an axial resolution of 5-10 $\mu$ m, it can provide close to in-vivo biopsy of the retina. Developing understanding of eye ailments such as tumors and muscular disorders is commonly conducted using OCT.

\*R.Maiti@sheffield.ac.uk (*Human Interaction Group, Mechanical Engineering Department, University of Sheffield, Broad Lane, Sheffield, S3 1JD*)

With close to 60 million contact lens users worldwide complaining of discomfort in the eye, it was important to develop a greater understanding of cornea, eyelid and lens interactions. OCT induced measurements were the first step to understanding the interaction between surfaces. The aim of the project was to measure the morphological parameters (thickness and roughness) of the cornea and eyelid of contact lens users and non-users before and after a period of 6-7 hours using OCT.

## 2. MATERIALS AND METHODS

### 2.1 Participants

Three contact lens users, age/gender: 60 yo/male; 19 yo/male; 22 yo/male who wore soft daily contact lenses (Table 1) and two non-users with no history of using contact lenses were recruited, age/gender: 20 yo/male; 30 yo/male. The volunteers were selected on a first-come first served basis with no history of major eye ailments. Recruited contact lens users were required to have available prescription lenses for use on the testing day. Informed consent was obtained from each participant prior to imaging and all participants received remuneration for their involvement. The University of Sheffield Medical Ethics team approved the study under the project reference 009483.

Table 2 shows the key protocol points for the eye study. One volunteer per day could be imaged due to time restrictions at the hospital. Each volunteer was asked to attend a morning session at 08:15 AM and an evening session at 17:30 PM. There were two imaging sessions scheduled during the day. The first session was conducted in the morning; the contact lens users were requested not to wear the contact lenses prior to the first session and the non-users were imaged as a control group. After a period of 6-7 hours, the second session was held where the contact lens and non-users were imaged again to quantify the difference in morphological parameters with respect to the first session.

Prior to imaging, each participant was asked to fill in a questionnaire about the details of their daily activities, contact lens type, fluid type and eye health including any current dry eye symptoms.

Table 1. Prescription lens types and brands used by contact lens users

Contact lens user	Lens type/ brand
1	Soft plastic - monthly replacement, Proclear
2	Soft plastic - daily disposable, Crystal
3	Soft plastic - daily disposable, Easy vision Specsavers

Table 2. An overview of the protocol for volunteer testing

Stage	Time	Description
1	08:15 – 08:30	The volunteer arrived at the hospital, agreed to the consent form and completed the eye questionnaire.
2	08:30 – 08:45	Slit lamp testing was conducted using fluorescein strips and saline solution which were placed in the eye, whereby the dye dispersed in eye. Photographs were taken of the cornea and the inverted upper eyelid with the correct light filter on the camera.
3	08:45 – 09:00	Images of the cornea and the inverted upper eyelid were captured using OCT.
4	09:00	Post imaging, the contact lens users were instructed to insert their prescription contact lenses and wear the lenses for a period of 6-7 hrs. Between stages 4 and 5 of the investigation, the user resumed their normal daily activities (such as work or university study) and returned to the hospital for imaging in stage 5.  Non-users did not wear contact lenses at any stage of the experiment. Non-users were instructed to carry out their normal daily activities and return to the hospital for imaging in stage 5.
5	17:30	The volunteer returned to the hospital for the second session of the day. Slit lamp and OCT imaging (Stages 2 and 3) of the protocol were repeated for

	contact lens users and non-users.
--	-----------------------------------

## 2.2 Imaging protocol

The cornea and eyelid were used as the imaging sites in this project, for each volunteer only the right eye was imaged. To image the portion of the eyelid in contact with a contact lens (for a contact lens users) or cornea (non-users), the eyelid was inverted inside out. Trained ophthalmology nurses were present to invert the eyelid and hold it during imaging process. All imaging for this study was performed using a slit lamp and Spectralis OCT (Figure 1), both located at the Royal Hallamshire Hospital, Sheffield. Fluorescein strips and saline solution were placed in the two sites. After dye dispersion, surface photographs using a slit lamp (Nietz-SI, Japan) with the correct light filter (Figure 2) were taken. Following slit lamp photographs, anterior segment Spectralis OCT (Heidelberg Engineering Gmph, Germany) was used to capture sub-surface layers of cornea and upper eyelid as shown in Figure 3. This system has A-scan rate of 40 kHz with 512 pixels scan size, 1.8 mm scan depth and 9 mm B-scan width.

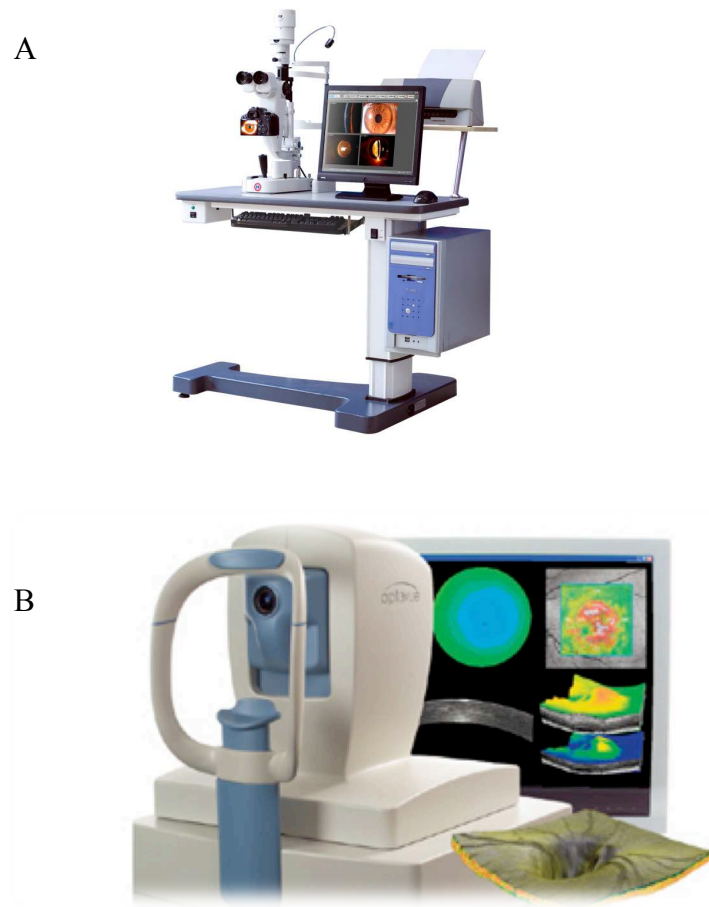


Figure 1. Equipment used in both the morning and evening sessions for contact lens users and non-users, A: Slit lamp (Nietz-SI, Japan) and B: Spectralis optical coherence tomography (Heidelberg Engineering Gmph, Germany).

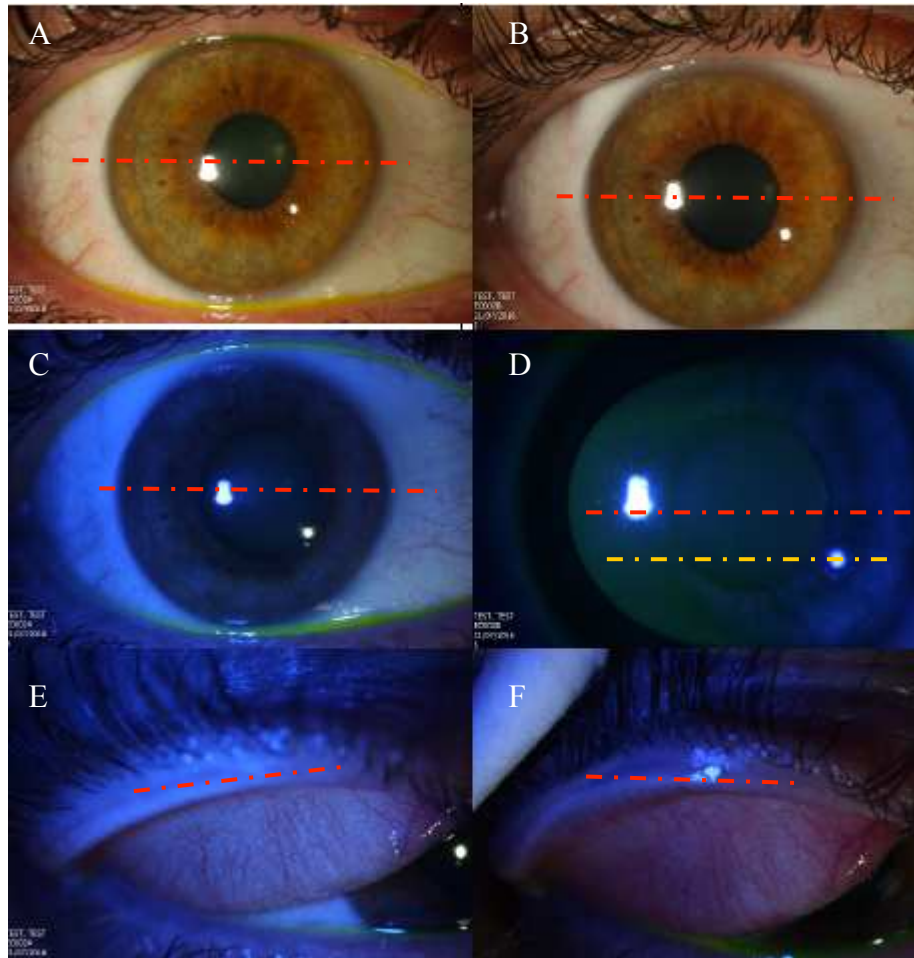


Figure 2. A selection of slit lamp images captured from a contact lens user at both skin sites (cornea and eyelid) before (A, C, E) and after (B, D, F) a period of 6-7 hours. The red lines show the axis of capturing images using OCT. The orange line is the axis where abrasion was detected. A, B) Cornea pictures using slit lamp with no filters. C,D) Cornea pictures using slit lamp with fluorescein filter. E, F) Inverted upper eyelid pictures with OCT images captured at red dotted lines.

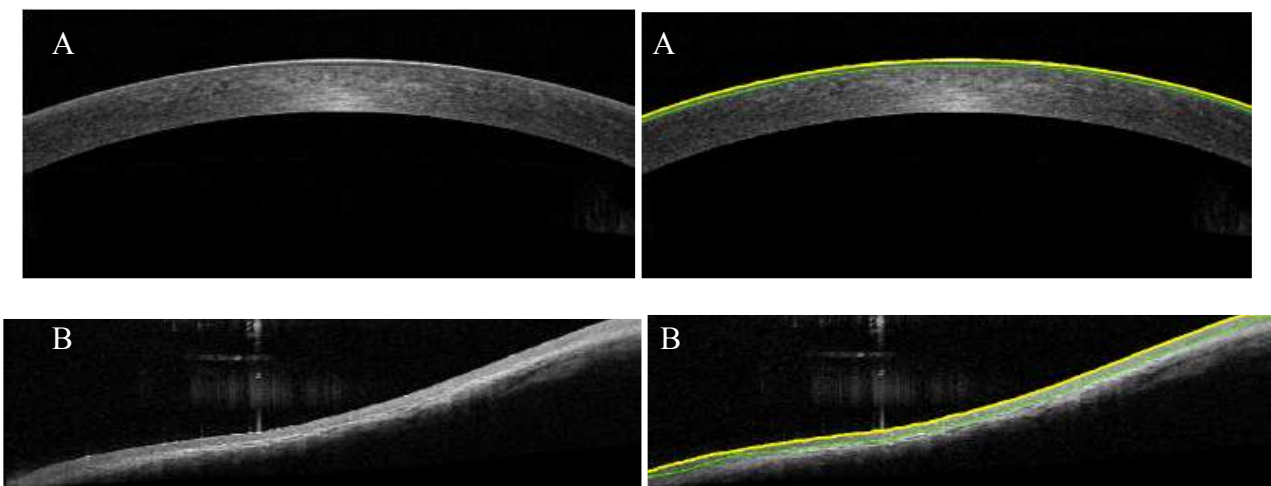


Figure 3. A selection of *OCT* images captured from both skin sites (A: Cornea and B: Eyelid) before and after the application of Michelson Diagnostic Algorithm. Images are color-coded for layers such that yellow line predicts the top layer of cornea and eyelid surfaces and green line for dermal-epidermal junction layer. The length of the images are 6 mm.

Imaging was first performed using a slit lamp along with a fluorescein dye to identify any abrasion on the eye. In the absence of abrasions, the cornea was imaged in the horizontal axis using the Spectralis OCT as shown in Figure 2. If abrasions were detected, the OCT images were captured on the abrasion site and horizontal axis. For the eyelid, images were captured only on the horizontal axis as shown in Figure 2.

### 2.3 Quantification of morphological parameters

The B-Scan images obtained from the Spectralis OCT were analyzed using the Michelson Diagnostic algorithm presented in Maiti et al.<sup>5</sup>. The algorithm determines the top and epithelium layers of both the cornea and eyelid based on the analysis of light reflectivity as shown in Figure 3. Based on the layer profiles, roughness and thickness of the sites (eyelid or cornea) were calculated. Five repeated scans were collected at each site to obtain an average roughness and thickness of the sites. The data was presented in mean  $\pm$  standard deviation. As data was sufficiently normally distributed and showed sufficiently homogenous variances, paired t-tests were applied to investigate for any significant difference between morphological parameters before and after sessions ( $p < 0.05$ ).

## 3. RESULTS AND DISCUSSION

Thickness and roughness measured using the Michelson Diagnostics algorithm are reported (Table 3) for both skin sites (cornea and eyelid) from the two sessions (before and after) in a period of 6-7 hours. Roughness and thickness of the cornea layers did not show any significant difference in contact lens users and non-users before and after the period of 6-7 hours ( $p > 0.1$ ). For example, the thickness of cornea for a contact lens volunteer increased by 4%. However, the increase was not significant ( $p = 0.2$ ). The roughness of the eyelid surface did significantly increase (1.6 to 3.6  $\mu\text{m}$  for contact lens and 1.4 to 4.7  $\mu\text{m}$  for non-contact lens volunteers). This increase might be due to abrasion of the eyelid surfaces or deposits of particles on the surface. The thickness of the epidermal layer in the eyelid showed 50% increase after wearing the contact lens for a prolonged time. This might be due to inflammation/irritation caused by the contact lens. However, tests capturing the cells from the eyelid should be analysed to confirm the increase in thickness. This inflammation however, was not present in the volunteers who were not wearing the contact lens.

One of the volunteers showed abrasion on the cornea after wearing the contact lenses. Further tests with large cohort of volunteers must be performed to report this result further. Though soft contact lenses are the most popular type of lens<sup>7</sup> in the market, the effect of hard contact lens should also be analysed to see the effect on the morphological parameters of cornea and eyelid surfaces. The authors hypothesize an increase in abrasion due to wearing hard contact lenses.

Table 3. Thickness and roughness of both cornea and eyelid layers pre and 6-7 hours post imaging for contact lens users and non-users. \* denotes the thickness or roughness between the two sessions is significant for  $p < 0.05$ .

User type	Layer location	Thickness in $\mu\text{m}$		Roughness in $\mu\text{m}$	
		Before	After	Before	After
Contact lens users (soft)	Cornea	52.0 $\pm$ 4.2	54.3 $\pm$ 3.5	1.1 $\pm$ 0.5	0.9 $\pm$ 0.5
	Eye lid	113.4 $\pm$ 7.8	173.0 $\pm$ 9.1*	1.6 $\pm$ 0.0	3.6 $\pm$ 0.8*
Non-users	Cornea	47.2 $\pm$ 2.1	45.5 $\pm$ 3.3	1.1 $\pm$ 0.6	1.0 $\pm$ 0.5
	Eye lid	111.5 $\pm$ 2.5	118.4 $\pm$ 7.2	1.4 $\pm$ 0.9	4.7 $\pm$ 1.3*

## 4. CONCLUSIONS

Wearing a soft contact lens for 6-7 hours showed an increase in the thickness of the eyelid. The roughness of the upper eyelid surface for contact lens users and non-users both increased by more than 50%. No significant changes were observed in the cornea. More experiments should be performed with higher cohort of volunteers to get a complete idea of the changes in morphological parameters. Overall, OCT with the Michelson Diagnostic Algorithm is a useful tool to predict the changes of surfaces interacting with contact lens.

## 5. ACKNOWLEDGEMENTS

This research was supported by the Sheffield University Research Experience grant and Engineering and Physical Science Research Council EP/K009699/1. The author would like to acknowledge Lutz-Christian Gerhardt, Rob Byers and Michelson Diagnostics for the skin layer detection algorithm.

## REFERENCES

1. Baar J. T. 2004 Annual Report. *Contact Lens Spectrum* (2005).
2. Riley, C., Young, G. & Chalmers, R. Prevalence of ocular surface symptoms, signs and uncomfortable hours of wear in contact lens wearers: the effect of refitting with daily wear silicone hydrogel lenses (senofilcon a). *Eye Contact Lens*. **32**, 281– 286 (2006).
3. Young, G., Veys, J., Pritchard, N. and Coleman, S. A Multi-centre study of lapsed contact lens wearers. *Ophthalmic Physiol Opt*. **22**, 516-527 (2002).
4. Bailey, S. Contact Lens Complications. *Optometry Today* 26-33 (1999).
5. Maiti, R., Gerhardt L-C., Lee, Z. S., Byers, R. A., Woods, D., Sanz-Herrera, J. A., Franklin, S. E., Lewis, R., Matcher, S. J. and Carré, M. J. In vivo measurement of skin surface strain and sub-surface layer deformation induced by natural tissue stretching. *J. Mech. Behav. Biomed. Mater.* **62**, 556–569 (2016).
6. Delacruz, J., Weissman, J. & Gossage, K. Automated measurement of epidermal thickness from optical coherence tomography images using line region growing. in (Kollias, N. et al.) 75480E (2010). doi:10.1117/12.842353
7. Morgan, P. B., Woods, C. A., Tranoudis, L. G. et. al. International Contact lens Prescribing in 2012 (2012) Available: <http://www.clspectrum.com/articleviewer.aspx?articleID=107854>.