



This is a repository copy of *Anatomical subgroup analysis of the MERIDIAN cohort: failed commissuration*.

White Rose Research Online URL for this paper:
<https://eprints.whiterose.ac.uk/117088/>

Version: Accepted Version

Article:

Griffiths, P.D. orcid.org/0000-0002-2706-5897, Brackley, K., Bradburn, M. et al. (9 more authors) (2017) Anatomical subgroup analysis of the MERIDIAN cohort: failed commissuration. *Ultrasound in Obstetrics & Gynecology*, 50 (6). pp. 753-760. ISSN 0960-7692

<https://doi.org/10.1002/uog.17502>

Reuse

Items deposited in White Rose Research Online are protected by copyright, with all rights reserved unless indicated otherwise. They may be downloaded and/or printed for private study, or other acts as permitted by national copyright laws. The publisher or other rights holders may allow further reproduction and re-use of the full text version. This is indicated by the licence information on the White Rose Research Online record for the item.

Takedown

If you consider content in White Rose Research Online to be in breach of UK law, please notify us by emailing eprints@whiterose.ac.uk including the URL of the record and the reason for the withdrawal request.



eprints@whiterose.ac.uk
<https://eprints.whiterose.ac.uk/>

Anatomical subgroup analysis of the MERIDIAN cohort: failed commissuration

Short title: iuMR for Failed commissuration

Paul D Griffiths PhD FRCR¹, Karen Brackley FRCOG DM², Michael Bradburn MSc³,
Daniel JA Connolly BSc MRCP FRCR⁴, Mary L Gawne-Cain MRCP, FRCR, MD²,
Daniel I Griffiths BSc⁵, Mark D Kilby DSc MD FRCOG, FRCPI⁶, Laura Mandefield
MSc³, Cara Mooney MSc³, Stephen C Robson MD MRCOG FRCP(Ed)⁷, Brigitte
Vollmer MD, PhD⁸, Gerald Mason MD FRCOG⁹

¹Academic Unit of Radiology, University of Sheffield, Glossop Road, Sheffield, S10 2JF, England ii) INSIGNEO Institute for in silico Medicine, University of Sheffield, UK, S10 2JF, ² University Hospital Southampton NHS Foundation Trust, UK SO16 6YD, ³Clinical Trials Research Unit, School of Health and Related Research, University of Sheffield, S1 4DA, ⁴Department of Radiology, Sheffield Children's Hospital, S10 2TH and the Royal Hallamshire Hospital, Sheffield Teaching Hospitals NHS Foundation Trust, S10 2JF, ⁵Academic Unit of Radiology, University of Sheffield, S10 2JF, ⁶i) Centre for Women's & Newborn Health, Institute of Metabolism & Systems Research, University of Birmingham, B15 2TT. ii) Fetal Medicine Centre, Birmingham Women's Foundation Trust (Birmingham Health Partners), Birmingham, B15 2TG, ⁷Newcastle University, Newcastle upon Tyne NE2 4HH, ⁸Clinical and Experimental Sciences University of Southampton and Southampton Children's Hospital, University Hospital Southampton NHS Foundation Trust SO16 6YD, ⁹Leeds Teaching Hospitals NHS trust, LS9 7TF

This article has been accepted for publication and undergone full peer review but has not been through the copyediting, typesetting, pagination and proofreading process, which may lead to differences between this version and the Version of Record. Please cite this article as doi: 10.1002/uog.17502

Corresponding author

Professor Paul Griffiths
Academic Unit of Radiology,
University of Sheffield,
Floor C, Royal Hallamshire Hospital
Glossop Road,
Sheffield, S10 2JF
England
Tel. +44 114 215 9604
Fax +44 114 271 1714
Email p.griffiths@sheffield.ac.uk

KEYWORDS: Fetus, Magnetic resonance imaging, Diagnostic accuracy, Agenesis of the corpus callosum, Hypogenesis of the corpus callosum

ABSTRACT

***Objective** To assess the contribution of in utero magnetic resonance (iuMR) imaging in fetuses diagnosed with either agenesis of the corpus callosum or hypogenesis of the corpus callosum (grouped as failed commissuration) on antenatal ultrasonography (USS) from the MERIDIAN cohort.*

***Methods** We report a sub-group analysis of fetuses with failed commissuration diagnosed on USS (with or without ventriculomegaly) from the MERIDIAN study who had iuMR imaging within 2 weeks of USS and outcome reference data were available. The diagnostic accuracy of USS and iuMR are reported as well as indicators of diagnostic confidence and effects on prognosis/clinical management.*

Results 79 fetuses with failed commissuration are reported (55 with agenesis and 24 with hypogenesis as the USS diagnoses). The diagnostic accuracy for detecting 'failed commissuration' as a group label was 34.2% for USS and 94.9% for iuMR (difference = 60.7%, 95% confidence interval 47.6% to 73.9%, $p < 0.0001$). The diagnostic accuracy for detecting hypogenesis of the corpus callosum as a discrete entity was 8.3% for USS and 87.5% for iuMR whilst the diagnostic accuracy for detecting agenesis of the corpus callosum as a distinct entity was 40.0% for USS and 92.7% for iuMR. There was a statistically significant improvement in 'appropriate' diagnostic confidence when using iuMR imaging as assessed by a score-based weighted average' method ($p < 0.0001$). Prognostic information given to the women changed in 36/79 (45.6%) cases after iuMR imaging and its overall effect on clinical management was 'significant', 'major' or 'decisive' in 35/79 cases (44.3%).

Conclusions Our data suggests that any woman whose fetus has failed commissuration as the only intracranial finding detected on USS should have iuMR imaging for further evaluation.

INTRODUCTION

The use of *in utero* MR (iuMR) imaging is increasing in clinical practice, primarily to investigate abnormalities of the fetal brain suspected on antenatal ultrasonography (USS). Its use is likely to increase further following the publication of the results of the ‘Magnetic Resonance imaging to enhance the diagnosis of fetal developmental brain abnormalities *in utero*’ (MERIDIAN) study¹. MERIDIAN was a large prospective multicentre study allowing recruitment of all types of brain abnormalities recognized on USS and showed an overall improvement in diagnostic accuracy of over 22%. The MERIDIAN researchers enlisted the assistance of fetal medicine focus groups at the planning stage of the study and one recommendation was to perform sub-group analyses on fetuses with specific brain abnormalities. Failed commissuration (agenesis of the corpus callosum [CC] and hypogenesis of the CC) was considered to be an important group in terms of both number of cases and the widely held view of fetal maternal experts that USS performs well in detecting those pathologies. If that was found to be correct it would be difficult to justify the use of iuMR imaging based on the extra expense incurred and discomfort to the pregnant women.

The original MERIDIAN report gave a synoptic overview of the diagnostic performance in this subgroup¹ but a more detailed description is warranted because of the complexity of the cases. In this paper we describe the performance of iuMR in characterizing brain abnormalities in fetuses when failed commissuration was the only finding suspected on USS. Specifically, we present data on diagnostic accuracy, diagnostic confidence and change in prognosis/clinical management brought about by including iuMR imaging in the diagnostic pathway.

METHODS

All of the cases reported in this paper were recruited into the MERIDIAN study and the overarching methodology of the MERIDIAN study is reported elsewhere¹ but the parts relevant to this paper are summarised here. MERIDIAN was undertaken in accordance with the Medicines for Human Use (Clinical Trials) Regulations 2004 and ethics approval was obtained for a multi-centre study through the Integrated Research Application System (62734). Recruitment was from 16 fetal medicine units in the UK and inclusion criteria for the main study were – pregnant women aged ≥ 16 years whose fetus had a brain abnormality detected by USS at a gestational age of 18 weeks or more, with no contraindications to iuMR and who were willing to provide written, fully informed consent to enter the study. This subgroup analysis describes those fetuses with either agenesis or hypogenesis of the CC as the only brain abnormality on USS either with or without associated ventriculomegaly (VM).

Antenatal imaging with ultrasonography and *in utero* MR imaging

All of the USS studies were performed by appropriately trained consultants in fetal medicine working in the NHS and each brain abnormality was listed using nomenclature from the “*ViewPoint*” antenatal ultrasound reporting software (GE Healthcare, Chalfont St Giles UK), along with an assessment of certainty of diagnosis for each brain abnormality using a 5 point Likert scale². The iuMR examinations were all performed on 1.5T superconducting clinical systems at one of six centres. The base requirement for the iuMR study was T2-weighted images of the fetal brain in the three orthogonal planes and a T1-weighted ultrafast sequence in at least one plane (usually axial). The reporting radiologist was aware of the diagnoses and the level of certainty

made on USS from the study paperwork but also had access to the full clinical USS report. The radiologist was required to comment on each brain abnormality recognised on USS (using ‘diagnosis excluded’ if the finding was not present on iuMR) and added extra anatomical diagnoses where appropriate onto a similar form as used for USS. Each entry was accompanied by an indicator of confidence using the same Likert scale as the USS assessment.

Outcome reference data and assessment of diagnostic accuracy

In cases where the pregnancy continued and the child survived, outcome reference data (ORD) was obtained from the clinical notes based on diagnoses made on postnatal neuroimaging studies up to the age of six months. In cases of termination of pregnancy, stillbirth or neonatal deaths the ORD was based on autopsy and/or post-mortem MR imaging. An independent paediatric neuroradiologist determined whether a full review of ORD by a Multidisciplinary Independent Expert Panel (MIEP) was required. Full review was required unless there was complete and unequivocal agreement between the anatomical findings on USS, iuMR and the ORD. The MIEP consisted of three NHS consultants (neuroradiologist, fetal medicine consultant, and paediatric neurologist) from a centre that did not recruit into MERIDAN and they were asked to judge whether the USS-based diagnoses and iuMR-based diagnoses had complete agreement with the ORD. The analysis on participants who underwent iuMR within 14 days of USS and for whom ORD was available consisted of the calculation of diagnostic accuracy for USS and iuMR studies defined as;

$$[\text{true positives} + \text{true negatives}] / \text{Total number of cases}$$

In this context, we define the first group ‘isolated failed commissuration’ as either USS diagnoses of agenesis or hypogenesis of the CC as the only brain abnormality (with or without VM) i.e. correctness was judged only by the presence of either corpus callosum abnormality and the absence of another brain lesion. The two subsequent analyses targeted the corpus callosum diagnoses directly by requiring the specific diagnoses ‘agenesis of the CC’ or ‘hypogenesis of the CC’ to be correct when compared with ORD, ignoring the presence of any other brain lesions. Diagnostic accuracies were calculated for USS and iuMR and compared using McNemar’s test.

Assessment of diagnostic confidence

In line with the report of the whole cohort, the first analysis of diagnostic confidence simply describes the proportion of USS and iuMR diagnoses made with high and low confidence that were either correct or incorrect. ‘High confidence’ diagnoses were defined as 70% or 90% certainties and low confidence diagnoses were 10%, 30% or 50% certainties for this analysis.

Our previous publication describes the significant limitations of the conventional assessments of diagnostic confidence¹, even if the Omary correction³ is used. The major limitation occurs because those methods do not require confirmation that the diagnoses are either correct or incorrect (i.e. no ORD are required). All of the cases in this study have ORD and we have chosen to use the ‘score-based weighted average’ method described by Ng and Palmer⁴ as our preferred method of describing ‘appropriate’ diagnostic confidence. As highlighted in our previous publication⁵ this approach uses not only diagnostic confidence assessments but also indicators of diagnostic accuracy as provided by the MIEP specifically: was the overall diagnosis

correct for iuMR, was the overall diagnosis correct for USS, which imaging method described the most severe pathology. This aspect was combined with a binary assessment of diagnostic confidence as either ‘high’ or ‘low’ as described above. An algorithm modified from Ng and Palmer⁴ (Figure 1) was used to define a route label for each case and hence derive a route score ranging from -4 to +4. Zero indicated no change in ‘appropriate’ confidence, whilst positive values indicate a benefit arising from the introduction of iuMR and negatives indicate that iuMR had a detrimental effect on analysis, the larger the number the greater the effect. For example, if USS described agenesis of the CC as the only intracranial abnormality with high confidence but iuMR excluded the diagnosis agenesis of the corpus callosum with high confidence the ‘score-based weighted average’ result will depend on the ORD. If agenesis of the corpus callosum is excluded on ORD the route label is A3 with a route score +3, which indicates improved diagnostic impact of iuMR, whereas if ORD confirmed agenesis of the corpus callosum the route label is F5 with a route score -4, which indicates a detrimental impact for iuMR. The integer scores for all cases were plotted as a histogram and described in terms of the number of cases in which iuMR reported with greater confidence (positive scores) and the number of cases with reduced confidence (negative scores). The mean, standard deviation and 95% confidence intervals were calculated and one sample t-tests were carried out to determine if the calculated scores differed from zero.

Assessment of effects on prognosis and clinical management

MERIDIAN collected data from the fetal medicine specialists about any changes in clinical management brought about by iuMR as described in detail elsewhere¹, but to summarise they were asked if:

- a) iuMR provided extra diagnostic information
- b) iuMR led to a change in prognosis
- c) iuMR led to a change in management (including if termination of pregnancy was offered)

With respect to analysis of prognostic information the fetal medicine experts were asked to define what prognostic information was given to the woman on the basis of the USS scan (but before iuMR) based on the following five categories:

- 1) Normal - no worse than the risk to a fetus without a demonstrable brain abnormality
- 2) Favourable - Normal neurological outcome expected in >90% of cases
- 3) Intermediate - Normal neurological outcome expected in 50 to 90% of cases
- 4) Poor - Normal neurological outcome expected in <50% of cases
- 5) Unknown

At the next consultation with the woman (where the iuMR report was available) the clinician recorded the updated prognostic information using the same five categories. For the purposes of description in this report we describe if the prognosis remained the same, worsened or improved after iuMR. This approach is straightforward when prognoses were in groups 1) to 4) or if the prognosis was 'Unknown' on both USS and iuMR. Difficulties arise when the prognosis on one imaging method was given as 'Unknown' but specified as 1) to 4) on the other. We have elected to interpret:

- USS prognosis ‘Unknown’, iuMR prognosis ‘Normal’ or ‘Favourable’ = improved prognosis
- USS prognosis ‘Unknown’, iuMR prognosis ‘Intermediate’ = no change in prognosis
- USS prognosis ‘Unknown’, iuMR prognosis ‘Poor’ = worse prognosis
- USS prognosis ‘Normal’ or ‘Favourable’, MR prognosis ‘Unknown’ = worse prognosis
- USS prognosis ‘Intermediate’, MR prognosis ‘Unknown’ = no change in prognosis
- USS prognosis ‘Poor’, MR prognosis ‘Unknown’ = no change in prognosis

Clinicians were also asked if termination of pregnancy was offered because the abnormalities on USS only were sufficient to consider that option under Ground E of the Abortion Act (section 1(1)(d) – substantial risk of serious mental or physical handicap).⁶ They were subsequently asked if the previous decision about offering termination of pregnancy was still valid after the iuMR information was available.

RESULTS

‘Failed commissuration’ featured as a diagnosis on USS in 92/570 (16.1%) fetuses from the main MERIDIAN cohort. Of these, 13 were excluded due to the presence of additional conditions other than VM, leaving 79 cases (13.9%) included in this study. 54 of the cases had associated VM, and in 51 the iuMR study was performed when the fetus was 18-23 weeks gestational age. Hypogenesis of the CC was the specific diagnosis on USS in 24/79 fetuses and agenesis of the CC in 55/79.

Diagnostic accuracy

The findings on USS and iuMR are compared with ORD in table 1. When ‘isolated failed commissuration’ was assessed as a group, the diagnostic accuracy of USS was 34.2% compared with 94.9% for iuMR, giving an improvement in diagnostic accuracy of 60.7% (95% confidence interval (CI) 47.6% to 73.9%, $p < 0.0001$). As explained in the methods section, there are two types of USS miscalls that contribute to the 52 errors in this group namely; a) a normal corpus callosum ORD (46 errors) and b) USS missed another brain abnormality shown on ORD (12 errors). Note that the two categories are not mutually exclusive and 5/12 fetuses with other brain abnormalities also had a normal corpus callosum and those cases are only attributed as having one miscall, hence the overall error rate of 52/79. All of the twelve other brain abnormalities shown on ORD were correctly diagnosed on iuMR imaging so all four of the errors for iuMR listed in table 1 concerned the state of the corpus callosum. Details of the 12 fetuses (15.2%) with other brain abnormalities are shown in table 2 and representative cases are shown in figures 2-5. Cortical formation abnormalities were found in 10/12 fetuses, an

absent septum pellucidum in 1/12 fetuses and a parenchymal posterior fossa abnormality in the other.

The overall diagnostic accuracy of USS and iuMR in diagnosing hypogenesis or agenesis of the CC correct as discrete entities (irrespective of the presence of other brain abnormalities) are presented in table 1 and the nature of the errors are shown in tables 3a (USS) and 3b (iuMR imaging). The diagnostic accuracy for detecting hypogenesis of the CC as a discrete entity was 8.3% on USS and 87.5% on iuMR (difference = 79.2%, 95% CI 55.1 to 100%, $p < 0.0001$) and the diagnostic accuracy for detecting agenesis of the CC as a distinct entity was 40.0% for USS and 92.7% for iuMR (difference = 52.7%, 95% CI 37.7 to 67.7%, $p < 0.0001$). The diagnosis of hypogenesis based on USS was correct in 2/24 fetuses (8.3%) - ORD showed a normal CC in 20/24 fetuses and agenesis of the CC in 2/24. The diagnosis of agenesis of the CC based on USS was confirmed on ORD in 22/55 cases (40.0%), 7/55 were hypogenesis of the CC on ORD and in 26/55 the CC was normal on ORD. The corpus callosum was thought to be normal in 45/79 fetuses on iuMR of which 43 (95.5%) were correct; the other two fetuses had hypogenesis of the CC. A diagnosis of hypogenesis of the CC was made on iuMR in 8/79 fetuses and was correct in 6/8 cases (75%), whilst the diagnosis of agenesis of CC made on iuMR was correct in 23/26 fetuses (88.5%).

Diagnostic confidence

Figure 6 presents the proportions of correct and incorrect diagnoses made with high and low diagnostic confidence. High confidence diagnoses were made in 29/79 (36.7%) fetuses on USS and 76/79 (96.2%) fetuses on iuMR, an increase of just under 60% of all

cases. On USS 13/29 (44.8%) high confidence diagnoses were incorrect in comparison with ORD, whilst on iuMR 5/76 (6.6%) high confidence diagnoses were incorrect indicating >6-times reduction of high confidence but incorrect diagnoses by iuMR when compared with USS. On USS 16/50 (32.0%) low confidence diagnoses were correct, whilst on iuMR all three low confidence diagnoses were correct (100%).

As described in the Methods section diagnostic accuracy data was combined with diagnostic confidence data in order to calculate a 'score-based weighted average' impact of (appropriate) diagnostic confidence as shown in figure 7. The overall mean difference was +1.51 (95% CI +1.14 to +1.87, $p < 0.0001$). In 60/79 the score was positive indicating an 'appropriate' improvement in diagnostic performance, 11/79 (14%) cases had a score was 0 (i.e. no effect) and was negative in 8/79 (10%) cases indicating a deleterious effect.

Prognosis and clinical management

The iuMR imaging studies provided extra diagnostic information compared with USS in 50/79 (63.3%) fetuses according to the referring fetal maternal consultants. Prognostic information given to the women of the iuMR study changed in 36/79 (45.6%) cases and in 20 fetuses the prognosis was worse after iuMR. This included all ten fetuses with cortical formation abnormalities as extra brain abnormalities, although the one case of absence of the cavum septum pellucidum did not have any effect on prognosis. In 16 fetuses the prognosis was improved after iuMR (including 14 cases with 'normal' or 'favourable' prognostic categories). Termination of pregnancy was offered to women on the basis of the USS findings alone in 26/79 (32.9%) cases and this increased to 39/79 (49.4%) after iuMR. In 21 cases termination of pregnancy was offered both

before and after iuMR imaging and in five cases the offer was revoked because of a normal iuMR (and confirmed on ORD). Termination of pregnancy was offered after iuMR and not on the basis of USS in 18 cases, which included nine fetuses with other brain malformations (all cortical formation abnormalities). The effect of iuMR on the final choice of clinical management was considered to be: No influence – 8/79, Minor influence – 36/79, Significant influence – 24/79, Major influence – 6/79, Decisive influence – 5/79.

Cases of failed commissuration identified on outcome reference data

Agenesis or hypogenesis of the CC featured as a diagnosis on ORD in 76/570 (13.3%) cases and 35/76 (46.1%) of those were not diagnosed on USS. In 23 fetuses the CC callosum abnormality on ORD was the only intracranial abnormality (except VM) hence other brain abnormalities were found in 53/76 (69.7%) cases of failed commissuration. Cortical formation and posterior fossa malformations featured highly amongst the other brain abnormalities.

DISCUSSION

The corpus callosum is the largest commissural structure in the human brain and as such is responsible for the majority of the connections between homologous areas of the cerebral hemispheres. Failure of the corpus callosum to form can either be complete (agenesis of the CC) or partial (hypogenesis of the CC)⁷ and failure of commissuration is a term that is often used to include both entities. This study consists of the 79 cases of the primary MERIDIAN cohort in which the abnormal CC was the only intracranial abnormality and was designed to look for improvements in diagnostic impact (diagnostic accuracy and diagnostic confidence) and changes in prognosis/clinical management by including iuMR in the clinical pathway.

Expert focus groups interviewed before the start of MERIDIAN recommended subgroup analysis in the three commonest fetal brain abnormalities detected on antenatal USS and the results of the VM⁸ and posterior fossa⁹ analyses are reported elsewhere. There are several reasons why the 'isolated failed commissuration' sub-group warrants specific study. It was the third commonest referral for iuMR in the MERIDIAN study (nearly 14% of all cases) and fetal medicine consultants, in general, believe that detection of agenesis of the CC with USS is relatively straightforward, although it was accepted that hypogenesis of the CC is more difficult. It should be noted agenesis of the CC was diagnosed on USS more than twice as often compared with hypogenesis of the CC in this study. There was, however, accumulating evidence from iuMR studies before the start of MERIDIAN that suggested the diagnosis of agenesis of the CC on USS may not be straightforward. Most publications comparing USS and iuMR of the fetal brain from that period described CC pathology as the biggest source of discrepancy between

USS and iuMR reports and this has been highlighted in systematic reviews/meta-analyses¹⁰⁻¹³. In addition, a recent publication from our group based on the experience of 7 years of iuMR studies immediately before the start of MERIDIAN raised serious questions about the ability of USS to diagnose failed commissuration¹⁴. That paper reported 121 fetuses with agenesis of the CC diagnosed on USS and showed that the diagnosis on USS was correct in less than 50% of cases (positive predictive value 47%, 95% CI 38 to 56%). A serious weakness of that study was the lack of ORD in all cases and the results of iuMR were taken as a surrogate reference standard. The major advantage of the current work is having ORD and the results confirm the worries raised in the earlier papers (Table 3). The diagnostic accuracy of USS is 34.2% for ‘isolated failed commissuration’, 8.3% for hypogenesis of the CC and 40% for agenesis of the CC as specific diagnoses. IuMR increased these by approximately 60%, 79% and 52% respectively. It is important to note from table 3b, however, that 6/7 of the errors made by iuMR in this paper had something to do with the diagnosis of hypogenesis of the CC. This is a topic for further iuMR imaging development and research and the use of 3D iuMR imaging is showing some progress¹⁵. Every indicator of diagnostic confidence in this group points to further improvements in diagnostic impact when iuMR is used. So, although the use of 3D USS and *post hoc* reconstructions are reported to improve visualization of the corpus callosum we must conclude from our data that iuMR imaging is imperative for the accurate diagnosis of corpus callosum abnormalities *in utero*¹⁵.

A further discussion point amongst the expert focus groups concerned the clinical significance of the diagnosis of agenesis/hypogenesis of the CC made *in utero* and some argued that it is not particularly important if the diagnosis is missed. This was

considered to be true only when the corpus callosum abnormality was an isolated finding because of the relatively low risk of neurodevelopmental problems in children. There are several publications to support that view and many clinicians quote a 70-80% chance of good clinical outcome in those cases^{16, 17}. Other studies, however, add the rider that the 'isolated' descriptor needs to be confirmed by iuMR imaging^{18, 19}. The results from our current prospective study suggest that fetal maternal experts in the UK consider agenesis and hypogenesis of the CC to be a clinically significant abnormality on two grounds. Firstly, nearly one third of the women reported in this were offered TOP on the basis of the USS findings. This point is underlined by the observation that in the five cases where iuMR did not confirm a CC abnormality (or other brain abnormality) the decision to offer TOP was reversed. On this level alone iuMR imaging is important to reduce the unnecessary worry for pregnant women, and a reduced risk of inappropriate termination of pregnancy. Secondly, the high rate of other brain pathologies subsequently identified by iuMR and confirmed on ORD (nearly 14%) usually led to worse prognoses being given. In 9/12 of such cases termination of pregnancy was offered after iuMR but not on the basis of USS results alone. As shown in the last paragraph of the results section in the entire MERIDIAN cohort agenesis or hypogenesis of the CC was found on ORD in 76/570 cases and in 46% the diagnosis was not made on USS and other brain abnormalities were found in nearly 70%. It is not surprising, therefore, that fetal medicine consultants considered the overall effect of iuMR on clinical management to be 'significant', 'major' or 'decisive' in over 44% of cases.

In conclusion, we have shown that USS has low diagnosis accuracy for abnormalities of the corpus callosum and the majority of the errors made on USS are corrected by using iuMR imaging. Our data suggests that a woman whose fetus has failed commissuration as the only intracranial finding on USS should have iuMR imaging for further evaluation.

ACKNOWLEDGMENTS

This project was funded by the National Institute for Health Research Health Technology Assessment Programme (project number 09/06/01). The views and opinions expressed therein are those of the authors and do not necessarily reflect those of the Health Technology Assessment Programme, NIHR, NHS or the Department of Health.

REFERENCES

1. Griffiths PD, Bradburn M, Campbell MJ, Cooper CL, Graham R, Jarvis D, Kilby MD, Mason G, Mooney C, Robson SC, Wailoo A. Use of MRI in the diagnosis of fetal brain abnormalities in utero (MERIDIAN): a multicentre, prospective cohort study. *The Lancet* 2016; doi: 10.1016/S0140-6736(16)31723-8
2. Likert R. A technique for the measurement of attitudes. *Archives of Psychology* 1932; **22**: 1–55
3. Omary RA, Kaplan PA, Dussault RG, Hornsby PP, Carter CT, Kahler DM, Hillman BJ. The impact of ankle radiographs on the diagnosis and management of acute ankle injuries. *Academic Radiology* 1996; **3**(9) : 758–765
4. Ng CS, Palmer CR. Analysis of diagnostic confidence and diagnostic accuracy: a unified framework. *The British Journal of Radiology* 2007; **80**(951) : 152–160.
5. Griffiths PD, Bradburn M, Campbell MJ, Cooper CL, Jarvis D, Kilby MD, Mason G, Mooney C, Robson SC, Wailoo A. Change in diagnostic confidence brought about by using *in utero* MR imaging for fetal structural brain pathology: Analysis of the MERIDIAN cohort. *Clin Radiol* (accepted, pending publication)
6. Abortion Act 1967 section 1
7. Barkovich AJ, Raybaud CA. Congenital malformations of the brain and skull. In: *Pediatric Neuroimaging* (5th Edition) Barkovich AJ, Raybaud CA (eds) Lippincott Williams & Wilkins, Philadelphia 2012; 367-568
8. Griffiths PD, Brackley K, Bradburn M, Connolly DJA, Gawne-Cain M, Griffiths DI, Kilby MD, Mandefield L, Mooney C, Robson SC, Vollmer B, Mason G.

- Anatomical subgroup analysis of the MERIDIAN cohort: Ventriculomegaly (under review)
9. Griffiths PD, Brackley K, Bradburn M, Connolly DJA, Gawne-Cain M, Kilby MD, Mandefield L, Mooney C, Robson SC, Vollmer B, Mason G. Anatomical subgroup analysis of the MERIDIAN cohort: Posterior fossa abnormalities (under review)
 10. Mundy L, Hiller J, Braunack-Mayer A, Merlin T. MRI for the detection of foetal abnormalities. *Adelaide: Adelaide Health Technology Assessment (AHTA)*. 2007; **15**(6)
 11. Rossi AC, and Prefumo F. Additional value of fetal magnetic resonance imaging in the prenatal diagnosis of central nervous system anomalies: a systematic review of the literature. *Ultrasound Obstet Gynecol* 2014; **44**(4) : 388–393
 12. Van Doorn M, Oude Rengerink K, Newsum EA, Reneman L, Majoie CB, Pajkrt E. Added value of fetal MRI in foetuses with suspected brain abnormalities on neurosonography: a systematic review and meta-analysis. *J Matern Fetal Neonatal Med* 2015; **29**(18): 2949-2961
 13. Jarvis D, Mooney C, Cohen J, Papaioannou D, Bradburn M, Sutton A, Griffiths PD. A systematic review and meta-analysis to determine the contribution of mr imaging to the diagnosis of foetal brain abnormalities In Utero. *Eur Radiol* 2016; DOI 10.1007/s00330-016-4563-4
 14. Craven I, Bradburn MJ, Griffiths PD. Antenatal diagnosis of agenesis of the corpus callosum. *Clin Radiol* 2015; **70** (3) : 248-253

15. Tonni G, Grisolia G, Sepulveda W. Second trimester fetal neurosonography: reconstructing cerebral midline anatomy and anomalies using a novel three-dimensional ultrasound technique. *Prenatal Diagnosis* 2014; **34**: 75–83.
16. Moutard ML, Kieffer V, Feingold J, Lewin F, Baron J-M, Adamsbaum C, Gélot A, Isapof A, Kieffer F, Billette de Villemeur T. Isolated corpus callosum agenesis: a ten-year follow-up after prenatal diagnosis (How are the children without corpus callosum at 10 years of age?). *Prenatal Diagnosis* 2012; **32**: 277–283.
17. Mangione R, Fries N, Godard P, Capron C, Mirlesse V, Lacombe D, Duyme M. Neurodevelopmental outcome following prenatal diagnosis of an isolated anomaly of the corpus callosum. *Ultrasound Obstet Gynaecol* 2011; **37**: 290e5.
18. Palmer EE, Mowat D. Agenesis of the corpus callosum: A clinical approach to diagnosis. *Am J Med Genet Part C Semin Med Genet* 2014; **166C**: 184–197.
19. Sotiriadis A, Makrydimas G. Neurodevelopment after prenatal diagnosis of isolated agenesis of the corpus callosum: an integrative review. *Am J Obstet Gynecol* 2012; **206**: 337e1-5.

CONFLICT OF INTEREST

The authors confirm that there are no conflicts of interest.

FIGURE LEGENDS

Figure 1. The algorithm used to provide the score-based weighted average data used to assess changes in appropriate confidence (modified from Ng and Palmer⁴).

Figure 2. A case of agreement between antenatal USS, iuMR imaging and outcome reference data. A diagnosis of agenesis of the corpus callosum was made with ‘very sure (90%)’ certainty on both USS and iuMR imaging (coronal MR image 2a and axial MR images 2b and 2c). Confirmation was made on postnatal imaging (not shown).

Figure 3. A case of disagreement between antenatal USS, iuMR imaging, based on the presence of other brain abnormalities. A fetus was referred at 36 weeks’ gestational age because of ventriculomegaly and a ‘very unsure (10%)’ diagnosis of agenesis of the corpus callosum on USS. IuMR imaging performed the same week confirmed ventriculomegaly and made a ‘very sure (90%)’ diagnosis of agenesis of the corpus callosum (3a-3c), which was associated with an inter-hemispheric cyst (arrowed on axial MR image 3a). A ‘sure (70%)’ certainty diagnosis of a nodular heterotopion was made as well (arrowed on coronal MR image 3b). All of those diagnoses were confirmed on post-mortem studies (courtesy of Dr A. Dean, Cambridge). Figure 3d is a superior view of the whole brain specimen with the hemispheres partially separated, showing agenesis of the corpus callosum and the inter-hemispheric cyst (arrowed on 3d). Figure 3e is a coronal section through the left hemisphere showing the heterotopion (arrowed) with microscopic confirmation in figure 3f (Luxol Fast Blue/Nissl), corresponding to the open rectangle on figure 3e.

Figure 4. A case of disagreement between antenatal USS and iuMR imaging, based on the presence of other brain abnormalities. A fetus referred at 30 weeks' gestational age because of ventriculomegaly and a 'sure (70%)' certainty diagnosis of agenesis of the corpus callosum on USS. IuMR imaging performed at 31 weeks confirmed ventriculomegaly and made a 'very sure (90%)' diagnosis of agenesis of the corpus callosum. This was associated with prominent germinolytic cysts (coronal MR image 4a and axial MR image 4c) and a 'very sure (90%)' diagnosis of an extensive bilateral cortical formation abnormality, probably polymicrogyria. All of those diagnoses were confirmed on postnatal MR imaging at 16 months (figures 4d-4f) although the germinolytic cysts had involuted.

Figure 5. Disagreement between antenatal USS, iuMR imaging, based on the corpus callosum abnormality and the presence of other brain abnormalities. A fetus referred for iuMR at 23 weeks' gestational age because of ventriculomegaly and an 'unsure (30%)' certainty diagnosis of agenesis of the corpus callosum on USS. IuMR imaging performed at 24 weeks confirmed ventriculomegaly (axial MR image 5a) and 'excluded' the diagnosis of agenesis of the corpus callosum (coronal MR image 5b). The frontal lobes showed reduced volume and irregular cortical plates bilaterally (coronal MR image 5b and axial MR image 5c) and a 'sure (70%)' diagnosis of polymicrogyria was made. The iuMR imaging findings were confirmed on post-mortem studies (courtesy of Dr A. Dean, Cambridge). Figure 5d is a left lateral view of the whole brain specimen showing poor development of the sylvian fissure. Figure 5e is an unstained coronal section of the right frontal lobe showing the irregular superior surface and 5f is the stained histological section (haematoxylin and eosin), which confirmed

polymicrogyria in the superior parts of the frontal lobes (c.f. the normal smooth cortex on the lateral convexity).

Figure 6. Histograms of ‘high confidence’ (70 or 90%) and ‘low confidence’ (10, 30 or 50%) diagnoses made on ultrasonography and in utero MR imaging. The red parts of the histograms indicate those diagnoses that were incorrect in comparison with outcome reference data. See text for details.

Figure 7. Graph of changes in ‘appropriate’ diagnostic confidence based on the score-based weighted average methods of Ng and Palmer⁴. See text for details.

Subgroup	USS Diagnoses		iuMR Diagnoses		Comparison of diagnostic accuracy		
	n	Number incorrect	Diagnostic accuracy	Number incorrect	Diagnostic accuracy	Difference (95% CI)	p-value*
Isolated failed Commissuration	79	52	34.2%	4	94.9%	60.7 (47.6, 73.9%)	<0.0001
Hypogenesis of the corpus callosum	24	22	8.3%	3	87.5%	79.2 (55.1, 100%)	<0.0001
Agenesis of the corpus callosum	55	33	40.0%	4	92.7%	52.7 (37.7, 67.7%)	<0.0001

Table 1. Diagnostic accuracy of ultrasonography and iuMR imaging in 79 fetuses with either agenesis or hypogenesis of the corpus callosum as the only structural brain abnormality on ultrasonography. ‘Isolated failed commissuration’ does not distinguish between hypogenesis or agenesis of the corpus callosum on outcome reference data therefore errors occur if the corpus callosum was normal on outcome reference data or if other brain abnormalities were present. ‘Hypogenesis of the corpus callosum’ and ‘Agenesis of the corpus callosum’ require these more restrictive anatomical diagnoses to be correct. See text for full details.

* McNemar’s test between USS and iuMR correct diagnoses

Case	USS diagnosis	Corpus callosum on ORD	Other brain abnormality on ORD	iuMR weeks	Corpus callosum on iuMR	Other brain abnormality on iuMR
146	Agenesis of the CC	Normal	Schizencephaly	28	Normal	Schizencephaly
199	Agenesis of the CC	Agenesis of the CC	Heterotopia	23	Agenesis of the CC	Heterotopia
254	Agenesis of the CC	Hypogenesis of the CC	Polymicrogyria	26	Agenesis of the CC	Polymicrogyria
421	Agenesis of the CC	Normal	Polymicrogyria	24	Normal	Polymicrogyria
448	Agenesis of the CC	Agenesis of the CC	Schizencephaly	24	Agenesis of the CC	Schizencephaly
520	Agenesis of the CC	Hypogenesis of the CC	Chiari II malformation	20	Hypogenesis of the CC	Chiari II malformation
786	Agenesis of the CC	Normal	Heterotopia	22	Normal	Heterotopia
809	Agenesis of the CC	Agenesis of the CC	Heterotopia	36	Agenesis of the CC	Heterotopia
858	Agenesis of the CC	Normal	Lissencephaly	23	Normal	Lissencephaly
940	Agenesis of the CC	Normal	Absent septum pellucidum	35	Normal	Absent septum pellucidum
942	Agenesis of the CC	Agenesis of the CC	Polymicrogyria	31	Agenesis of the CC	Polymicrogyria
952	Agenesis of the CC	Agenesis of the CC	Schizencephaly	26	Agenesis of the CC	Schizencephaly

Table 2. Summaries of the findings on ultrasonography and iuMR imaging in 12 fetuses with brain abnormalities other than failed commissuration on outcome reference data.

ORD=outcome reference diagnosis: CC= corpus callosum

	ORD Normal Corpus Callosum	ORD Hypogenesis of Corpus Callosum	ORD Agenesis of Corpus Callosum
USS diagnosis Hypogenesis of corpus callosum (n=24)	20	2	2
USS diagnosis Agenesis of corpus callosum (n=55)	26	7	22

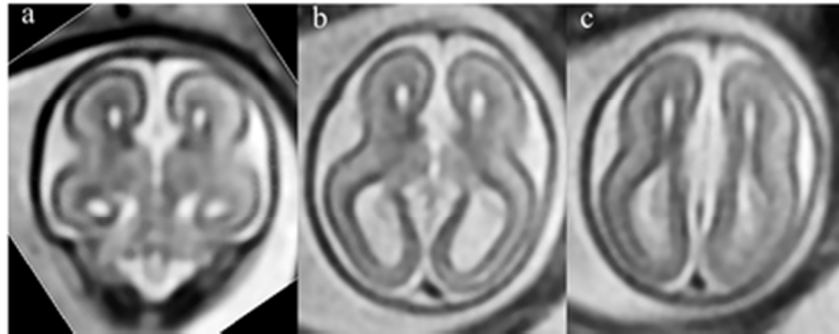
Table 3a

	ORD Normal Corpus Callosum	ORD Hypogenesis of Corpus Callosum	ORD Agenesis of Corpus Callosum
iuMR diagnosis Normal Corpus Callosum (n=45)	43	2	0
iuMR diagnosis Hypogenesis of Corpus Callosum (n=8)	1	6	1
iuMR diagnosis Agenesis of Corpus Callosum (n=26)	1	2	23

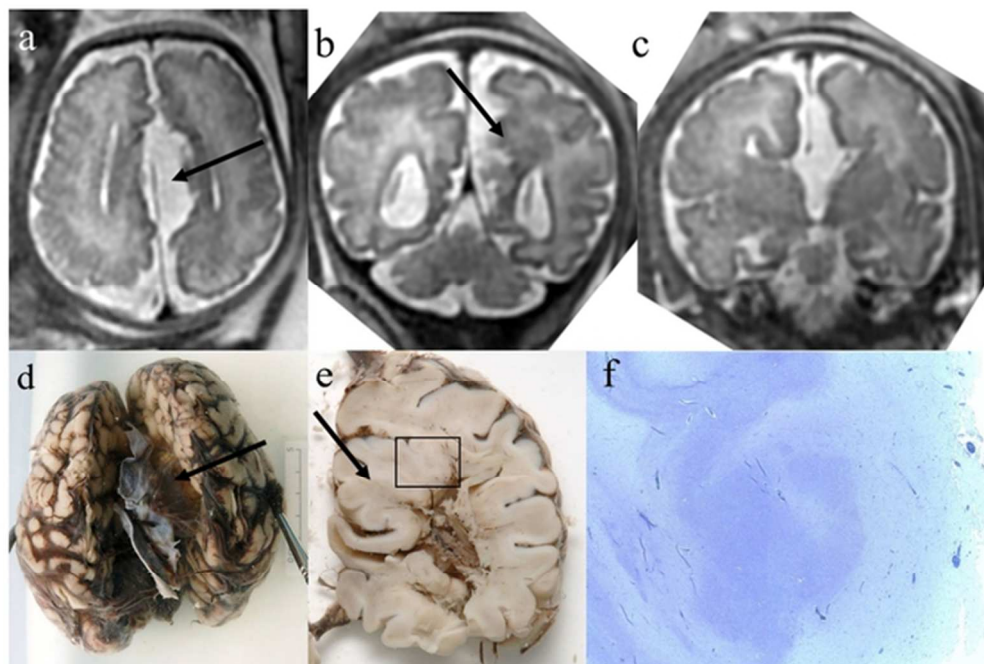
Table 3b

Table 3. Comparison of the state of the corpus callosum in 79 fetuses with failed commissuration diagnosed on ultrasound irrespective of the presence or absence of other brain abnormalities. Table 3a compares the diagnosis on ultrasonography with outcome reference data and table 3b compares the diagnosis on in utero MR imaging with outcome reference data.

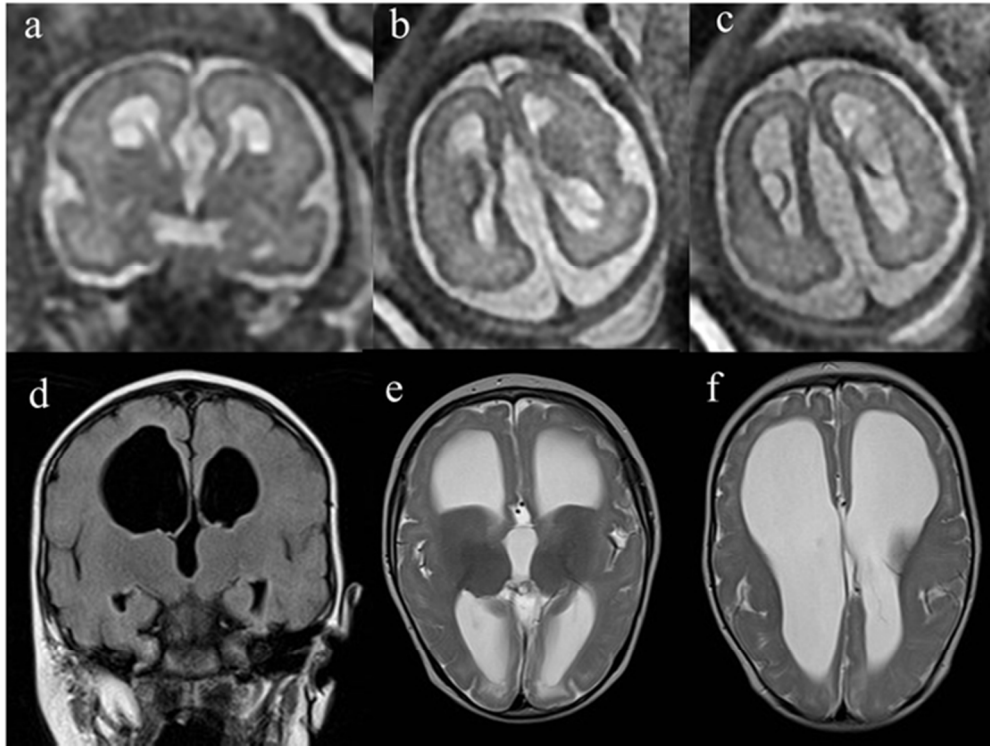
ORD = outcome reference diagnosis: CC = corpus callosum



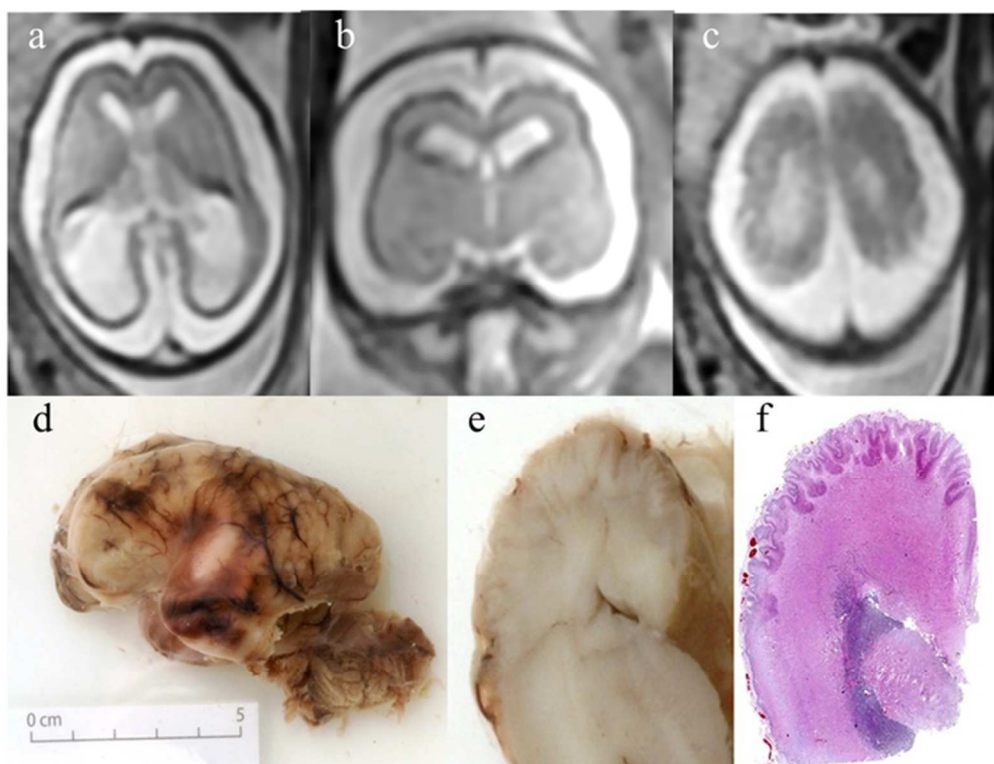
A case of agreement between antenatal USS, iuMR imaging and outcome reference data. A diagnosis of agenesis of the corpus callosum was made with 'very sure (90%)' certainty on both USS and iuMR imaging (coronal MR image 2a and axial MR images 2b and 2c). Confirmation was made on postnatal imaging (not shown).



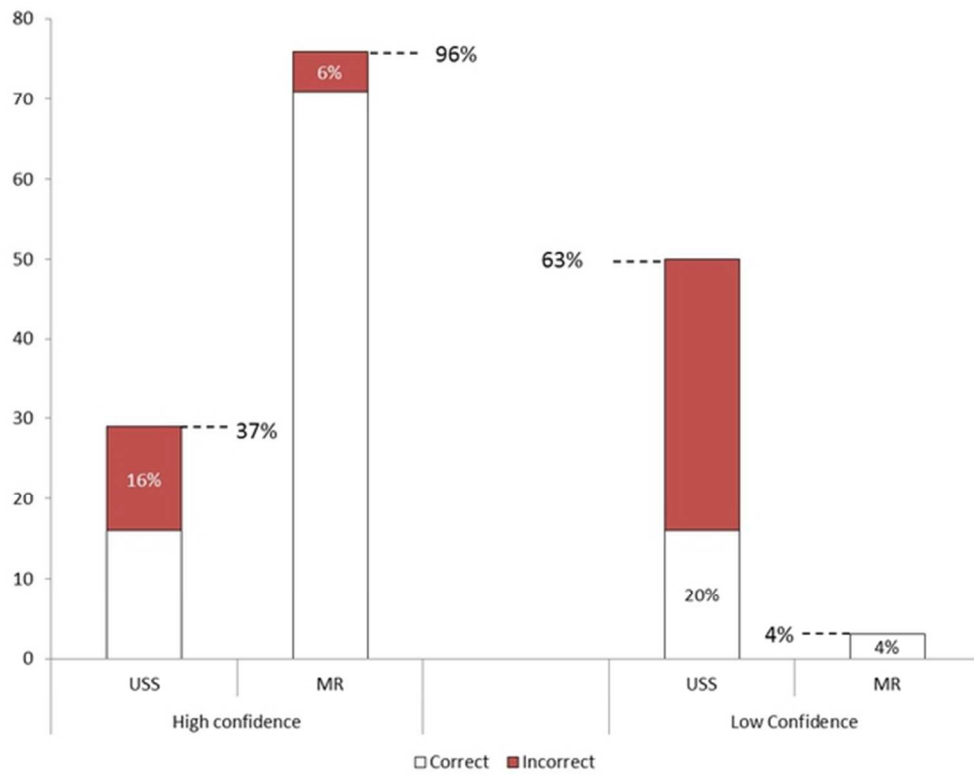
A case of disagreement between antenatal USS, iuMR imaging, based on the presence of other brain abnormalities. A fetus was referred at 36 weeks' gestational age because of ventriculomegaly and a 'very unsure (10%)' diagnosis of agenesis of the corpus callosum on USS. IuMR imaging performed the same week confirmed ventriculomegaly and made a 'very sure (90%)' diagnosis of agenesis of the corpus callosum (3a-3c), which was associated with an inter-hemispheric cyst (arrowed on axial MR image 3a). A 'sure (70%)' certainty diagnosis of a nodular heterotopion was made as well (arrowed on coronal MR image 3b). All of those diagnoses were confirmed on post-mortem studies (courtesy of Dr A. Dean, Cambridge). Figure 3d is a superior view of the whole brain specimen with the hemispheres partially separated, showing agenesis of the corpus callosum and the inter-hemispheric cyst (arrowed on 3d). Figure 3e is a coronal section through the left hemisphere showing the heterotopion (arrowed) with microscopic confirmation in figure 3f (Luxol Fast Blue/Nissl), corresponding to the open rectangle on figure 3e.



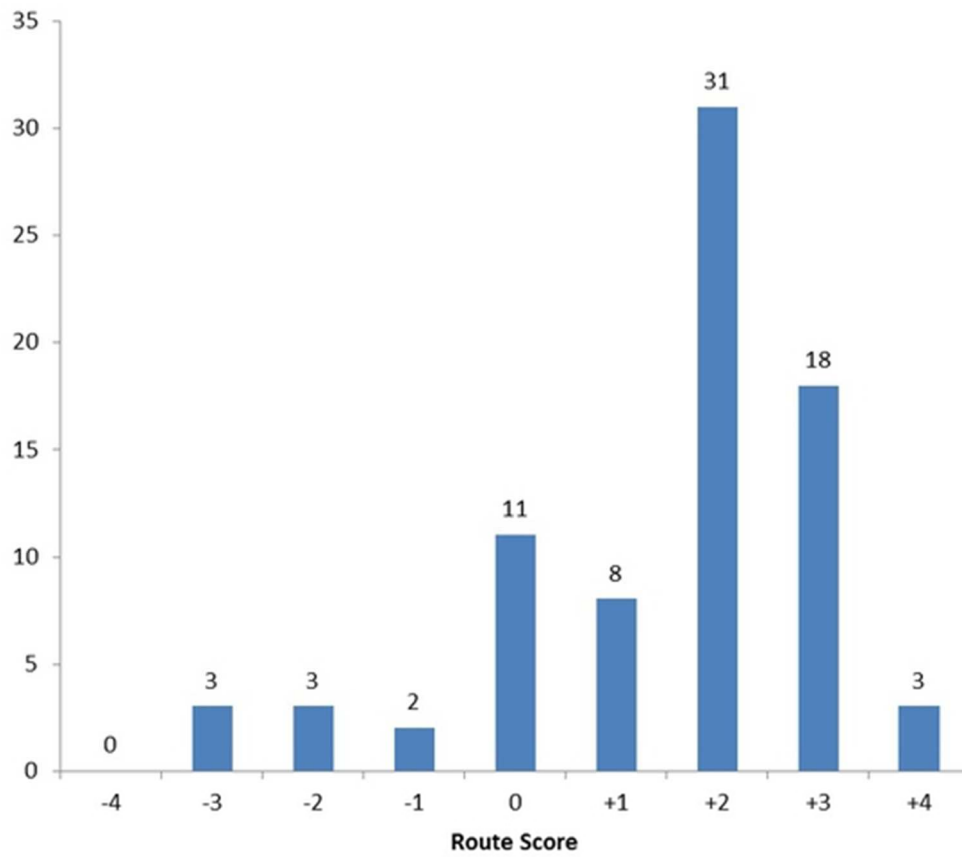
A case of disagreement between antenatal USS and iuMR imaging, based on the presence of other brain abnormalities. A fetus referred at 30 weeks' gestational age because of ventriculomegaly and a 'sure (70%)' certainty diagnosis of agenesis of the corpus callosum on USS. IuMR imaging performed at 31 weeks confirmed ventriculomegaly and made a 'very sure (90%)' diagnosis of agenesis of the corpus callosum. This was associated with prominent germinolytic cysts (coronal MR image 4a and axial MR image 4c) and a 'very sure (90%)' diagnosis of an extensive bilateral cortical formation abnormality, probably polymicrogyria. All of those diagnoses were confirmed on postnatal MR imaging at 16 months (figures 4d-4f) although the germinolytic cysts had involuted.



Disagreement between antenatal USS, iuMR imaging, based on the corpus callosum abnormality and the presence of other brain abnormalities. A fetus referred for iuMR at 23 weeks' gestational age because of ventriculomegaly and an 'unsure (30%)' certainty diagnosis of agenesis of the corpus callosum on USS. IuMR imaging performed at 24 weeks confirmed ventriculomegaly (axial MR image 5a) and 'excluded' the diagnosis of agenesis of the corpus callosum (coronal MR image 5b). The frontal lobes showed reduced volume and irregular cortical plates bilaterally (coronal MR image 5b and axial MR image 5c) and a 'sure (70%)' diagnosis of polymicrogyria was made. The iuMR imaging findings were confirmed on post-mortem studies (courtesy of Dr A. Dean, Cambridge). Figure 5d is a left lateral view of the whole brain specimen showing poor development of the sylvian fissure. Figure 5e is an unstained coronal section of the right frontal lobe showing the irregular superior surface and 5f is the stained histological section (haematoxylin and eosin), which confirmed polymicrogyria in the superior parts of the frontal lobes (c.f. the normal smooth cortex on the lateral convexity).



Histograms of 'high confidence' (70 or 90%) and 'low confidence' (10, 30 or 50%) diagnoses made on ultrasonography and in utero MR imaging. The red parts of the histograms indicate those diagnoses that were incorrect in comparison with outcome reference data. See text for details.



A graph of changes in 'appropriate' diagnostic confidence based on the score-based weighted average methods of Ng and Palmer⁴. See text for details.